LIFELONG LEARNING
FOR RADIOLOGY

AJR Integrative Imaging

American Roentgen Ray Society
ARRS

Supplement to the *American Journal of Roentgenology*

AJR December 2008, Vol. 191, No. 4, pp. S1–Sxx

American Roentgen Ray Society
ARRS

CME and SAM Information

Three of the articles in this issue of *AJR Integrative Imaging* offer SAM and CME credits.

CME Credit

The American Roentgen Ray Society (ARRS) is accredited by the Accreditation Council on Continuing Medical Education (ACCME) to sponsor continuing medical activities for physicians.

The ARRS designates this educational activity for a maximum of 4.5 credits toward the AMA Physician's Recognition Award. Each physician should claim only those credits that he or she actually spent in the activity.

- Up to 1.5 CME credits may be claimed for *MRI of Pelvic Floor Dysfunction: Self-Assessment Module.*
- Up to 1.5 CME credits may be claimed for *Interpretation and Clinical Applications of Breast MRI: Self-Assessment Module.*
- Up to 1.5 CME credits may be claimed for *Algorithmic Workup of Abnormal Vaginal Bleeding with Endovaginal Sonography and Sonohysterography: Self-Assessment Module.*

These CME articles consist of two parts: one, the text and related images appearing in this supplement; and two, the self-evaluation quiz, which is available online at www.arrs.org. You should read the articles, review the accompanying images, and refer to the articles referenced in this supplement, then complete the self-evaluation quiz. **To obtain CME credit you must complete the self-evaluation quiz online**. Visit www.arrs.org and go to the left-hand menu bar under Publications/Journals/SAM Articles. There is no charge for ARRS members to participate in this program. Nonmembers pay a fee to access CME and SAM material.

Date of release: November 19, 2008
Expiration date: November 18, 2009
Estimated time of completion: 4.5 hours

In compliance with the Essentials and Standards of the ACCME, authors of the CME activities in this publication are required to disclose all relevant financial relationships with any commercial interest to the ARRS. The ACCME defines "relevant financial relationships" as financial relationships in any amount occurring within the past 12 months that create a conflict of interest.

Drs. Fielding, Law, Lee, Maldonado, Mercado, Moy, Perez, Rodriguez, and *Shi*, have all indicated that they have no commercial interests to disclose.

SAM and CME Credit

MRI of Pelvic Floor Dysfunction: Self-Assessment Module. To obtain 1 SAM credit and 1.5 CME credits, you must follow the instructions on page SXX.

Interpretation and Clinical Applications of Breast MRI: Self-Assessment Module. To obtain 1 SAM credit and 1.5 CME credits, you must follow the instructions on page SXX.

Algorithmic Workup of Abnormal Vaginal Bleeding with Endovaginal Sonography and Sonohysterography: Self-Assessment Module. To obtain 1 SAM credit and 1.5 CME credits, you must follow the instructions on page SXX.

MRI of Pelvic Floor Dysfunction: Self-Assessment Module, Interpretation and Clinical Applications of Breast MRI: Self-Assessment Module, and *Algorithmic Workup of Abnormal Vaginal Bleeding with Endovaginal Sonography and Sonohysterography: Self-Assessment Module* are qualified by the American Board of Radiology (ABR) in meeting the criteria for self-assessment toward the purpose of fulfilling requirements in the ABR Maintenance of Certification. To obtain SAM credit, visit www.arrs.org and go to the left-hand menu bar under Publications/Journals/SAM Articles.

COVER ART CREDIT: Xxxxxx
XXXX
XXXX

COVER ARTWORK SUBMISSIONS

If you would like to have your photograph or illustration considered for the front cover of *AJR Integrative Imaging*, please submit it via www.arrs.org. Click on the *Publications, Journals, AJR II Authors* link for more details.

American Roentgen Ray Society
ARRS

AJR

Integrative Imaging

LIFELONG LEARNING FOR RADIOLOGY

A supplement to the *American Journal of Roentgenology* Volume 191, No. 4, December 2008

Printed in the U.S.A.

Instructions for Authors

A complete set of *AJR* Instructions for Authors, including information about figure processing and electronic submission requirements, can be found at www.arrs.org.

AJR Integrative Imaging submissions should follow the formats outlined below.

1. Reviews and Self-Assessment Modules

Although these articles may have a variety of formats (see specific types below), common elements include educational objectives, multiple-choice self-assessment questions that refer directly to the educational objectives, explanation of the correct and incorrect responses, and references. It is expected that some multiple-choice questions may be case-based. Each illustration should have a detailed description, either in the legend or in the text, and include the age, sex, and condition of the patient, as well as a description of the technology used to produce the image (e.g., endoluminal 3D CTC image of 32-year-old man with…).

Author instructions: The review portion of the manuscript should have 5,000–10,000 words of text, 10–25 figure parts, and as many references as needed. The self-assessment portion should have a least 10 four-option multiple-choice questions with complete solutions. The multiple-choice questions should have a single best response, and should be acceptable to the American Board of Radiology (ABR). The multiple-choice questions may be used to introduce the case discussions, to assess comprehension, or both. The solution to each multiple-choice question should explicitly state why each of the answer options is or is not the best response, and should have at least one reference. Redundancy of information presented in the solutions with that presented in the article text is to be expected.

Type 1. *Case-based:* This format consists of a set of educational case scenarios related by a theme. The case presentations consist of the clinical presentation, the rationale for imaging, a description of the images, four-option multiple-choice questions, explanations of the best and incorrect responses, and concluding commentary. The exact format depends on the particular case. The theme that relates the cases may be any combination of anatomy, clinical presentation, pathophysiology, technique, demographics, etc. These articles should have a minimum of six case scenarios. The following is an example of a case-based review and SAM (Editor's note: Fewer case scenarios were required at the time this SAM was qualified by the ABR):

- Chew FS. Radiology of the Hands: Review and Self-Assessment Module. *AJR* 2005; 184[suppl]:S157–S168

Type 2. *Evidence-based:* This format consists of discussions of one or more clinical management issues. The scientific evidence for different courses of management is presented in the context of illustrative case scenarios. These articles should have a minimum of six case scenarios. The following is an example of an evidence-based review and accompanying self-assessment module (Editor's note: Fewer multiple choice questions were required at the time this SAM was qualified by the ABR):

- Attili AK, Cascade PN. CT and MRI of Coronary Artery Disease: Evidence-Based Review. *AJR* 2006; 187[suppl]: S483–S499
- Attili AK, Foral JM, Schoepf J, Cascade PN, Chew FS. CT and MRI of Coronary Artery Disease: Self-Assessment Module. *AJR* 2006; 187[suppl]:S500–S504

Type 3. *Pictorial essay (clinically or pathophysiology-based):* This format consists of an exposition on a clinically or pathophysiology-based topic with extensive illustrations. The following is an example of a pictorial review and self-assessment module (Editor's note: Fewer multiple-choice questions were required at the time this SAM was qualified by the ABR):

- Poon CS, Chang J-K, Swarnkar A, Johnson MH, Wasenko J. Radiologic Diagnosis of Cerebral Venous Thrombosis: Pictorial Review. *AJR* 2007; 189[suppl]:S64–S75
- Poon CS, Chew FS. Radiologic Diagnosis of Cerebral Venous Thrombosis: Self-Assessment Module. *AJR* 2007; 189[suppl]:S76–S78

Type 4. *Review article:* This format consists of a traditional review article with a large number of references. Illustrative cases and multiple-choice questions may be used to introduce or review topics. The following is an example of a review article and self-assessment module (Editor's note: Fewer multiple-choice questions were required at the time this SAM was qualified by the ABR):

- Momeni AK, Roberts CC, Chew FS. Imaging of Chronic and Exotic Sinonasal Disease: Review. *AJR* 2007; 189[suppl]: S35–S45
- Momeni AK, Roberts CC, Chew FS. Imaging of Chronic and Exotic Sinonasal Disease: Self-Assessment Module. *AJR* 2007; 189[suppl]:S46–S48

Type 5. *Self-assessment module without accompanying review*: This format consists of educational objectives, a list of required educational activities that are external to the SAM itself (such as published articles or Web content), 10 or more multiple-choice questions that refer to the educational objectives and activities, and complete solutions that explain each answer option and provide references.

The following is an example of a self-assessment module without accompanying review (Editor's note: Fewer multiple-choice questions were required at the time this SAM was qualified by the ABR):

- Ko JP, Roberts CC, Berger WG, Chew FS. Imaging Evaluation of the Solitary Pulmonary Nodule: Self-Assessment Module. *AJR* 2007; 188[suppl]:S1–S4

2. Radiological Reasoning

These are case presentations that step the reader through an expert's analysis of a difficult case. The case is presented progres-

sively, with the expert's thought process described in detail. Concluding comments tie up loose ends and provide references and additional relevant factual material. Clinical reasoning presentations should fit on approximately five journal pages. The title of the article should reflect the clinical or imaging presentation, not the specific pathologic diagnosis. The abstract should include the diagnosis and the take-home message of the article.

Author instructions: 2,000–4,000 words, NOT including the multiple choice questions and solutions, 5–10 figure parts. Three voices: case presenter, expert discussant, and expert commentator. Do not include a review of the literature because these may be found elsewhere (e.g., textbooks and actual review articles). Each article should be followed by five four-option multiple-choice questions that will be used to assess comprehension. Each of the best and non-best responses should be explicitly explained in the solutions, and each solution should have at least one reference.

Radiological reasoning articles are often used as required reading for self-assessment modules (see SAM Type 5, above), therefore, authors of radiological reasoning manuscripts are strongly encouraged to submit a companion self-assessment module manuscript at the same time. The following is an example of a radiological reasoning article and accompanying self-assessment module (Editor's note: Fewer multiple choice questions were required at the time this SAM was qualified by the ABR):

- Liu PT. Radiological Reasoning: Acutely Painful Swollen Finger. *AJR* 2007; 188:[suppl]S13–S17
- Roberts CC, Liu PT, Chew FS. Imaging Evaluation of Tendon Sheath Disease: Self-Assessment Module. *AJR* 2007; 188:S10–S12

3. Teaching File

Teaching file cases are standard cases that are well illustrated, typically with an interesting twist. Unlike case reports, which seek to extend the frontiers of knowledge, teaching file cases are intended as exemplars of known appearances and presentations of disease, with the goal of educating the reader. The standard presentation includes clinical history, clinical images, radiologic description, focused differential diagnosis, final diagnosis, and commentary. An abstract should be prepared that provides an educational objective and a conclusion. The title of the article should reflect the clinical or imaging presentation rather than the specific pathologic diagnosis. Authors should provide two four-option multiple-choice questions with complete solutions. Each of the best and non-best responses should be explicitly explained in the solutions, and each solution should have at least one reference. Authors will need to provide indexing terms and coding.

Teaching file cases should be 1,000–2,000 words, NOT including the multiple-choice questions and solutions, and typically no more than eight figure parts. Some teaching file manuscripts may be selected for publication as Web exclusives. Teaching File cases are often used as required reading for self-assessment modules (see SAM Type 5, above), therefore, teaching file manuscripts that are amenable to such use or are accompanied by a companion self-assessment module manuscript are much more likely to receive serious consideration. The following is an example of a teaching file article and accompanying self-assessment module (Editor's note: Fewer multiple choice questions were required at the time this SAM was qualified by the ABR):

- Sutcliffe JB III, Bui-Mansfield LT. AJR Teaching File: Intermittent Claudication of the Lower Extremity in a Young Patient. *AJR* 2007; 189[suppl]:S17–S20
- Chew FS, Bui-Mansfield LT. Imaging Popliteal Artery Disease in Young Adults with Claudication: Self-Assessment Module. *AJR* 2007; 189[suppl]:S13–S16

AJR

Integrative Imaging

LIFELONG LEARNING FOR RADIOLOGY

A supplement to the *American Journal of Roentgenology* Volume 191, No. 6, December 2008

Table of Contents

[Note to Dr. Chew: Do we want to leave "in a Patient with a History of Induced Abortion" in the title?]

MRI of Pelvic Floor Dysfunction: *Review*

Yan Mee Law[1,2] and Julia R. Fielding[2]

OBJECTIVE

The purpose of this article is to review the anatomy and etiology of pelvic floor weakness in women and to discuss the role of MRI in the assessment of female pelvic floor dysfunction.

CONCLUSION

In women with pelvic floor weakness, pelvic MRI, with its superior soft-tissue contrast resolution, allows direct visualization of the pelvic organs and their supportive structures in a single noninvasive examination. By providing useful and valuable information on the extent and severity of pelvic organ prolapse, MRI plays a valuable role in preoperative planning of complex cases.

Introduction

Weakening of the female pelvic floor is a prevalent and debilitating disorder. It results in abnormal descent of the urinary bladder, the uterovaginal vault, and the rectum, resulting in urinary continence, fecal incontinence, and pelvic organ prolapse. Pelvic floor weakening affects approximately 50% of women older than 50 years at a direct annual cost of $12 billion [1, 2]. It is a major health issue in older women, as shown by the 11.1% lifetime risk of undergoing a single operation for pelvic organ prolapse and urinary incontinence, as well as the large proportion of reoperations [3].

Pelvic floor weakness has many complex causes. The risk factors for pelvic floor dysfunction include pregnancy, multiparity, advanced age, menopause, obesity, connective tissue disorders, smoking, chronic obstructive pulmonary disease, and any other factors that result in a chronic rise in intraabdominal pressure. A consensus conference statement from the National Institutes of Health concluded that age, sex, and vaginal parity are established risk factors [4]. Although epidemiologic evidence supports the relation between vaginal delivery and pelvic floor dysfunction [5], not all women who undergo vaginal delivery develop pelvic floor dysfunction [6], and not all nulliparous women are free from pelvic floor dysfunction [7]. Data and electromyographic studies also suggest that vaginal delivery causes neuromuscular damage to the pelvic floor well before the onset of pelvic floor dysfunction [8]. The support structures of the female pelvis consist of a complex network of pelvic muscles, fascia, and ligaments. Weakness of the pelvic musculature, ligaments, and fascia support result in abnormal descent of the pelvic floor organs and debilitating symptoms related to urinary or bowel incontinence, sexual dysfunction, and pelvic organ prolapse.

Anatomy

The pelvic floor is divided into three compartments (Fig. 1). The anterior compartment contains the urinary bladder and the urethra; the middle compartment contains the uterus, cervix, and vagina; and the posterior compartment contains the rectum. The support for these structures arises from the attachment of the muscles, fascia, and ligaments to the bony pelvis. MRI allows visualization of all three compartments and is extremely useful in assessing women who have symptoms of multicompartment prolapse before complex pelvic floor surgery is undertaken. The vagina, being the middle viscera and from its lateral attachments to the pelvic side walls via the ligaments, is the middle divider that determines the nature of any pelvic organ prolapse.

The pelvic fascia, pelvic floor musculature, and fascial condensations called ligaments are the primary supporting structures of the female pelvis. The endopelvic fascia is the most superior layer and forms a continuous sheet extending cephalad from the uterine artery to the point at which the vagina fuses with the levator muscles below. The endopelvic fascia covers the levator ani muscles and the pelvic viscera in a continuous sheet. Laterally, the condensation of the endopelvic fascia forms the arcus tendineus, providing lateral support to and anchoring the levator ani muscles. The endopelvic fascia also attaches the cervix and vagina to the pelvic side wall via the elastic condensations known as the parametrium and paracolpium, respectively. The parametrium is made up of the cardinal and uterosacral ligaments and

Keywords: cystocele, MRI, pelvic floor dysfunction, rectocele

DOI:10.2214/AJR.07.7096

Received April 24, 2008; accepted without revision June 17, 2008.

[1]Department of Diagnostic Radiology, Singapore General Hospital, Outram Rd., Singapore 169608, Republic of Singapore. Address correspondence to Y. M. Law (law.yan.mee@sgh.com.sg).

[2]Department of Radiology, The University of North Carolina at Chapel Hill, Chapel Hill, NC.

AJR 2008;191:SXX–SXX 0361–803X/08/1916–SXX

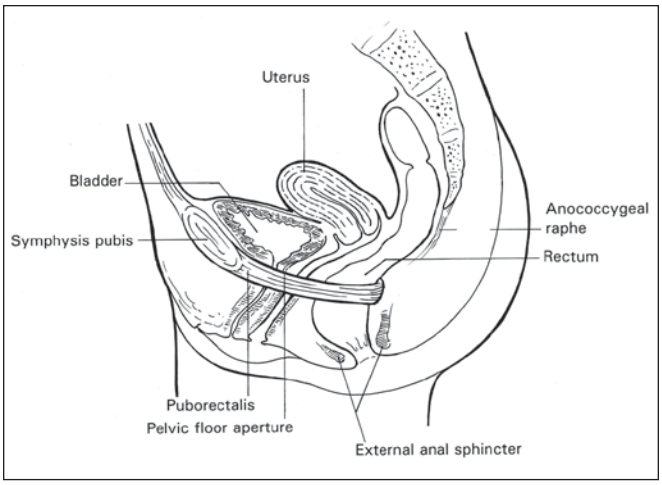

A

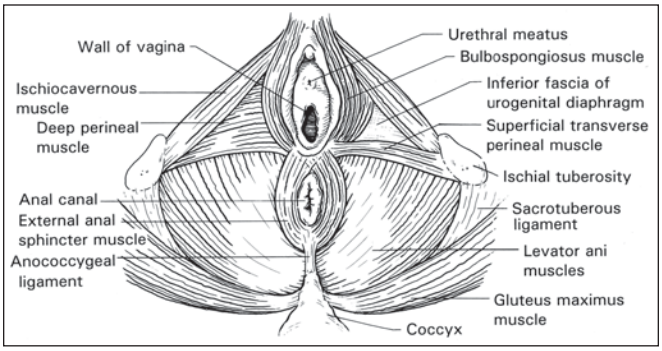

B

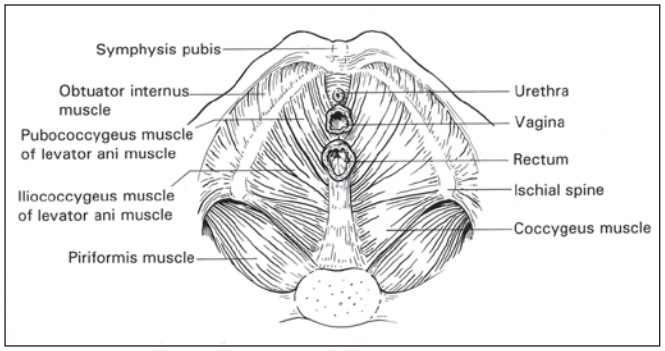

C

Fig. 1—Anatomy of the pelvic floor in women.
A–C, Sagittal (**A**) and axial (**B** and **C**) line drawings show pubococcygeus and iliococcygeus muscles that are major component of levator ani muscles. Pubococcygeal line is drawn from most inferior portion of pubic symphysis to last horizontal sacrococcygeal line on midsagittal MR image. In contrast to what is shown on **A,** anococcygeal raphe, also known as levator plate, is usually parallel to pubococcygeal in normal subjects. (Reprinted with permission from Cardozo L. *Urogynecology*. New York, NY: Churchill-Livingstone, 1997:325–326 [41])

provides support to the body of the uterus. The paracolpium stretches the vagina transversely between the urinary bladder and the rectum. The endopelvic fascia forms a supportive layer, the pubocervical fascia, between the pubis, the urinary bladder, and the anterior vaginal wall. Similarly, posteriorly the endopelvic fascia forms a supportive layer, the rectovaginal fascia, between the posterior vaginal wall and the rectum, that prevents the rectum from protruding forward and the bowel from herniating inferiorly. These fascial condensations are not well visualized on conventional MRI; their defects may be inferred indirectly through secondary findings. These ligaments may be visualized with an endovaginal coil that is placed near the target organ and allows higher resolution and signal-to-noise ratio (SNR) than a surface or body coil and can therefore provide more detailed visualization of fine structures [9]. This is especially useful for evaluation of the urethra and its supporting structures in the evaluation of stress urinary incontinence [9]. The distal vagina is directly attached to its surrounding structures: anteriorly to the urethra, posteriorly to the perineal body, and laterally with the levator ani muscles.

The levator ani muscles lie deep in relation to the endopelvic fascia. The two components of the levator ani that provide the major support to the pelvic organs are the puborectalis and the iliococcygeus muscles. The puborectalis forms a sling around the rectum and plays an important role in apposing the orifices of the pelvic floor as well as elevating the bladder neck and compressing it against the pubic symphysis. The iliococcygeus has a horizontal orientation, arises from the external anal sphincter, and fans out laterally, attaching to the arcus tendineus. Posteriorly and in the midline, the iliococcygeus condenses to form a firm raphe anterior to the coccyx known as the levator plate. The iliococcygeus muscle acts as an important physical barrier, preventing posterior compartment prolapse. The muscles of the pelvic floor and levator plate are well visualized on MRI.

The perineal membrane lies inferior to the levator ani muscles and separates the vagina and rectum. It is a dense structure and is the point of insertion of five muscles: the deep transverse perineal muscle, the superficial muscles of the perineal membrane, the external urethral sphincter, the external anal sphincter, and the levator ani. The perineal body prevents expansion of the urogenital hiatus, which is the opening in the levator ani muscle groups through which the urethra, vagina, and rectum course; it is also the orifice through which pelvic organ prolapse occurs. The perineal membrane may be damaged during vaginal delivery via an episiotomy.

It is the weakness of these supporting muscles, fascia, and ligaments that results in pelvic floor relaxation. This

weakness progresses with age and may be related to menopause and hypoestrogenemic states. Loss of support to the urinary bladder and the urethra results in prolapse of the urinary bladder and protrusion of the anterior vaginal wall, forming a cystocele, which may result in urinary incontinence. Weakness of the parametrium and paracolpium causes prolapse of the cervix and uterus, and weakness of the rectovaginal fascia results in prolapse of the rectum and protrusion of the posterior vaginal wall, forming a rectocele, and may result in fecal incontinence. Prolapse of the small bowel through the rectovaginal fascia results in an enterocele. In patients who have undergone a hysterectomy, prolapse of the vaginal apex can arise because of weakness of the paracolpium, resulting in apical prolapse.

Imaging

In women with symptoms of pelvic floor weakness, physical examination is essential for diagnosing pelvic organ prolapse. Most patients with mild symptoms of pelvic floor weakness, such as mild urinary continence, may benefit from a thorough physical examination and urodynamic studies. In patients with moderate to severe symptoms, such as severe urinary incontinence, procidentia, fecal incontinence, or symptoms suggesting a complex pelvic floor disorder, physical examination may be inadequate, and imaging will be useful. Studies have reported poor sensitivity and specificity of physical examination in diagnosing various forms of pelvic floor dysfunction [10]. Several studies have also shown that patients with urinary incontinence have coexistent pelvic organ prolapse in the other two compartments that requires surgical repair [11–13]. Accurate assessment of all compartments of the pelvic floor is therefore essential in planning surgical reconstruction in order to minimize the risk of recurrence and repeated surgery.

Traditional imaging methods in assessment of pelvic floor weakness include urodynamics, voiding cystourethrography, ultrasonography of the bladder neck and anal sphincter, and fluoroscopic cystocolpodefecography. In the past decade, MRI has emerged as a competitor to these techniques in the assessment of pelvic floor dysfunction. Although MRI is not indicated for the routine assessment of all patients with mild symptoms of pelvic floor dysfunction, it is certainly an invaluable tool in preoperative planning because it provides detailed anatomic information and may alter the management of patients. In assessing the influence of MR defecography on surgical therapy in patients with fecal incontinence, Hetzer et al. [14] showed that findings on MRI led to a change of surgical therapy in 67% of patients in whom some form of surgery was required to treat fecal incontinence. In some centers, MRI is routinely used in preoperative planning before pelvic floor surgery [15].

In recent years, MRI has been shown to be effective in revealing pelvic floor dysfunction. It allows concomitant visualization of all three compartments of the pelvic floor and at the same time allows direct visualization of the pelvic support muscles and organs. With advances in technology, new machines and new sequences have allowed increased SNR as well as faster acquisition times. In most instances, dynamic MRI examination of the pelvic floor is performed with the patient in the supine or lateral decubitus position, which does not mimic the normal physiologic state. MRI defecography performed in a 0.5-T open MR system or fluoroscopic cystocolpodefecography, both of which are performed with the patient in the sitting position, more closely resemble the physiologic state. Although visibility of laxity in the pelvic floor in patients with pelvic floor dysfunction may be increased on sitting MRI compared with supine studies, Bertschinger et al. [16] compared sitting MR defecography with dynamic supine MRI and showed that sitting MR defecography is not superior to dynamic supine MRI for depiction of clinically relevant bladder descent and rectoceles. Similarly, the study by Fielding et al. [17] showed that although a greater degree of pelvic floor laxity was shown on MRI in the sitting position, it was not superior to standard supine MRI.

Moreover, in a 0.5-T open MRI system, one must contend with images of a lower SNR and soft-tissue resolution. MRI shows enteroceles with a high degree of accuracy when compared with physical examination and fluoroscopic cystodefecography [18, 19]. Other studies show that dynamic supine MRI and fluoroscopic defecography have similar detection rates for rectocele [20]. Another advantage of MRI is that it provides additional information about the contents of the enterocele, which may include small bowel, omentum, mesenteric fat, or large bowel. MRI allows better visualization than other techniques of the uterus, cervix, and rectovaginal space and hence increases the conspicuity of posterior compartment prolapse. Many different MRI techniques are described in the literature for imaging of the pelvic floor that may or may not require opacification of the pelvic organs [21–23]. The pelvic organs may be opacified by instilling ultrasonic gel into the vagina and rectum [23].

Imaging Technique

In MRI of the pelvis, adequate patient preparation and a good technique with fast acquisition time are required to achieve maximum patient comfort and hence better patient compliance. The patient will be asked to void partially before the dynamic examination in order to prevent a distended urinary bladder from obscuring the pelvic structures and masking pelvic organ prolapse. Maintaining a small amount of urine in the urinary bladder improves visualization of the bladder and anterior vaginal wall prolapse. The examination is performed with a torso phased-array coil wrapped around the pelvis. Although use of an endovaginal coil may improve the spatial resolution of the fine supporting ligaments in the pelvis, it is invasive and may diminish patient acceptance and compliance [9]. The use of an endovaginal coil may distort

TABLE 1: Suggested Protocol for Dynamic MRI of Pelvic Floor Dysfunction

Sequence	Plane	TR	TE	FOV	Slice Thickness / Gap	Matrix[a]	NEX
Localizer	Sagittal	5	15	350–400	10 mm / 0	160 × 256	
HASTE[b]	Sagittal	4.4	90	300	10 mm / 0	128 × 256	1
T2-weighted turbo spin echo	Axial	7,000	132	200	3 mm / interleaved	270 × 256	1
T2-weighted turbo spin echo	Coronal	7,000	132	200	5 mm / 1 mm	270 × 256	2

Note—FOV = field of view, NEX = number of excitations.
[a]Frequency × phase.
[b]This sequence is repeated at rest and maximal strain and may be substituted for other ultrafast pulse sequence such as true fast imaging with steady-state precession.

the pelvic tissues in patients with a small pelvis. The field of view is small and often inadequate for visualization of the puborectalis. To improve visualization of the vagina and rectum, a small volume of intraluminal ultrasonic gel that has a hyperintense T2 signal may be instilled. Via a small-caliber catheter-tip syringe, 20 mL of gel may be instilled into the vagina and approximately 60–120 mL into the rectum. Although the dynamic MRI examination may be performed without endoluminal gel, doing so results in suboptimal straining that masks the degree of pelvic organ prolapse and results in inconspicuity of visceral descent.

Ultrafast, large-field-of-view, T2-weighted sequences such as single-shot fast spin-echo (SSFSE, GE Healthcare scanners) or half-Fourier acquisition turbo spin-echo (HASTE, Siemens Medical Solutions scanners) are frequently described in dynamic MRI of the pelvic floor and are performed at our institution. Alternatively, true fast imaging in steady-state precession may be performed. The patient should be given instructions as to the proper performance of straining before the examination. Specifically, she should be told to keep her sacrum on the table and strain using only the internal organs. The images are acquired in the sagittal plane and can be viewed in a cine loop to visualize the pelvic floor and the degree of prolapse of the pelvic organs.

For patients with a rectocele, these images should be repeated after the patient evacuates the rectal contents. The evacuation sequence can be obtained with the patient in the magnet and recorded if the magnet has been adequately prepared and the patient is able to cooperate with instructions. However, if the patient cannot evacuate in the magnet, evacuation in the commode followed by repeated imaging may be necessary. Residual contrast material will define a significant rectocele. In patients with pelvic organ prolapse, static images may be acquired in the coronal plane. These images show ballooning of the iliococcygeus muscle that often occurs with chronic constipation and perineal hernias.

After the dynamic examination is completed, small-field-of-view (20–24 cm) T2-weighted axial fast spin-echo (FSE, GE Healthcare scanners) or axial turbo spin-echo (TSE, Siemens Medical Solutions scanners) sequences are acquired to obtain high-resolution images of the muscles and fascia of the pelvic floor and the fascial condensations supporting the urethra. Although this set of images requires approximately 4 minutes to acquire, images of the lower pelvis are resistant to breathing motion artifacts. These high-resolution axial images of the pelvis are useful in showing the relationship between the pelvic side wall and the urethra and vagina. Fat saturation is generally not applied to these sequences because the hyperintense signal of fat in the pelvis provides good contrast to the hypointense signal of the adjacent muscles, fascia, and pubic bones. The entire examination is typically completed in 20 minutes. A suggested protocol for MRI of pelvic floor dysfunction is summarized in Table 1.

Interpretation of MRI Findings

The level of the pelvic floor on dynamic MRI can be demarcated radiologically on the midsagittal image using the pubococcygeal line as described by Yang et al. [22] (Fig. 2). This line extends from the most inferior portion of the pubic symphysis to the last horizontal sacrococcygeal joint. This line is easily drawn and highly reproducible on MRI in all patients. The levator plate should be parallel to the pubococcygeal line in normal individuals. Furthermore, two other reference lines, the H and M lines, are used, which may be a useful guide in identifying pelvic floor relaxation and prolapse [24]. The H line measures the distance from the inferior symphysis pubis to the posterior anorectal junction on the midsagittal image and is indicative of the anteroposterior width of the levator hiatus. The M line is drawn perpendicular from the pubococcygeal line to the most distal aspect of the H line and is indicative of the descent of the levator hiatus from the pubococcygeal line. In the study by Comiter et al. [24], the H line and M line in normal women measured approximately 5 and 2 cm, respectively.

The presence of significant pelvic floor prolapse will result in sloping of the levator plate and increasing length of the H and M lines, indicating widening and descent of the levator hiatus. Although elongation of the H and M lines is a useful indication of pelvic floor dysfunction and pelvic organ prolapse, little is described in the literature quantifying the severity of prolapse using these reference lines. Therefore, the presence of pelvic organ prolapse on MRI should be interpreted in correlation with the severity of the patient's clinical symptoms.

The high-resolution T2-weighted axial images of the pelvic floor should be analyzed for signal intensity, symmetry,

thickness, and fraying of the pelvic floor muscles. The vagina is suspended between the urethra and the rectum by the paracolpium and should maintain a normal butterfly configuration and be well centered in the pelvis in women with normal anatomy (Fig. 3). Although the periurethral ligaments may not be clearly shown without an endovaginal coil, wherever possible the symmetry and integrity of the periurethral ligaments should be analyzed, especially in women with symptoms of urinary incontinence.

Urinary Incontinence and Anterior Compartment Prolapse

Urinary incontinence in women is divided into stress urinary incontinence, urge urinary incontinence, and overflow urinary incontinence. Stress urinary incontinence is the involuntary loss of urine due to an increase in intraabdominal pressure such as coughing and sneezing; it is related to urethral sphincter deficiency. Urge and overflow urinary incontinence are related to bladder abnormalities. In urge incontinence, there is detrusor instability or damage to the nervous system supplying the urinary bladder, such as in multiple sclerosis, stroke, or pelvic injury, and a large amount of urine leaks when the patient experiences a sudden urge to urinate. In overflow incontinence, a small amount of urine leaks when the urinary bladder is overdistended because of weakness of the bladder muscles in a neurogenic bladder or in chronic bladder outlet obstruction. Overflow incontinence is less common in women than in men.

Assessment and treatment of women with symptoms of urinary incontinence and pelvic floor weakness are multidisciplinary exercises involving urologists, urogynecologists, psychologists, physical therapists, and radiologists. Treatment begins with conservative measures such as pelvic floor exercise, use of a pessary, and lifestyle modifications. When these techniques are ineffective, surgery is required.

Support of the urethra arises from the pelvic muscles and fasciae. Condensations of the endopelvic fascia provide ligamentous support of the urethra. In a study of supporting

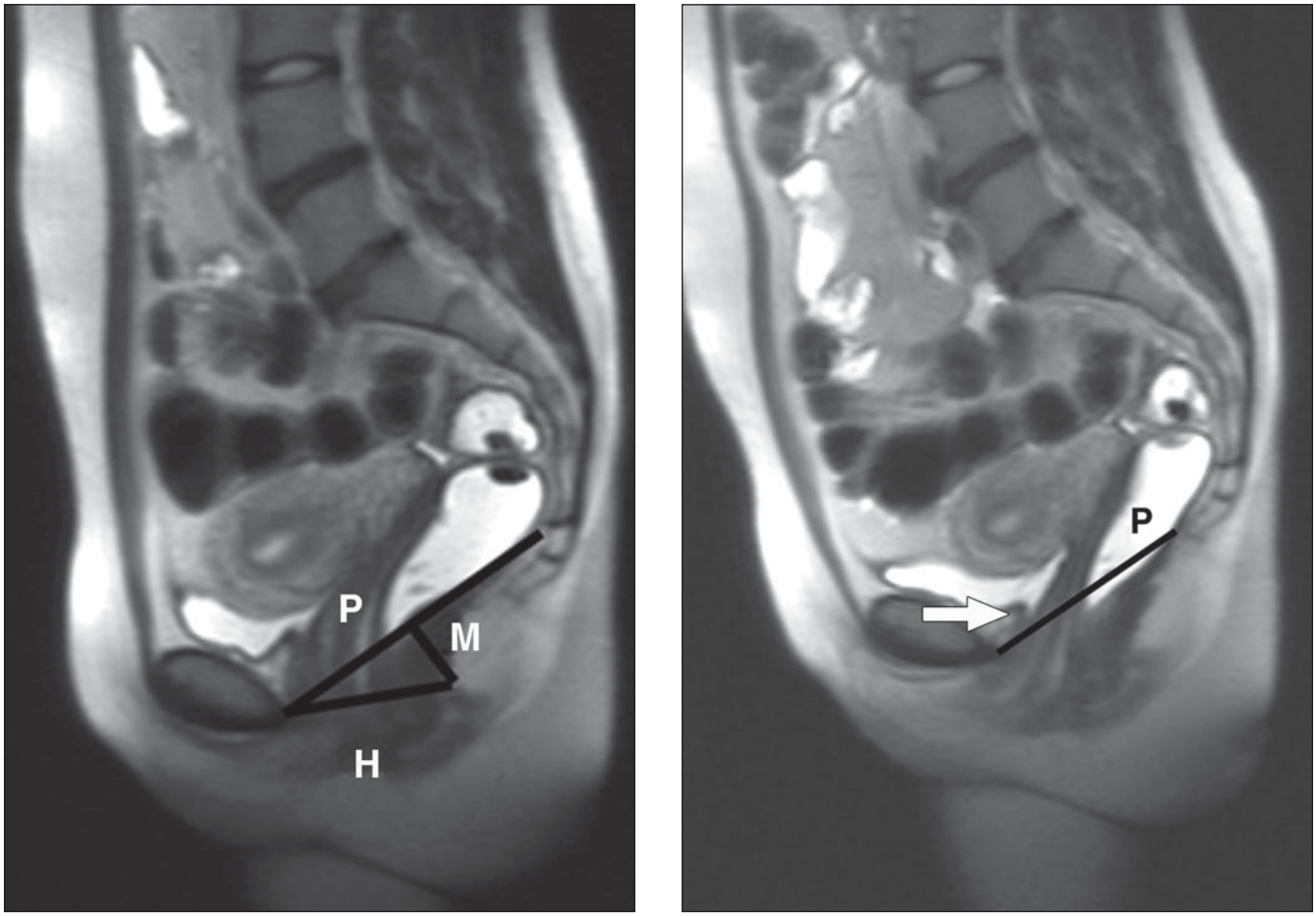

A B

Fig. 2—22-year-old woman with mild symptoms of pelvic floor weakness.
A and **B,** Sagittal HASTE MR images of female pelvis show normal position of pelvic viscera at rest (**A**) and when straining (**B**). P, H, and M indicate normal pubococcygeal and H and M lines. Arrow in **B** indicates normal position of bladder neck when straining.

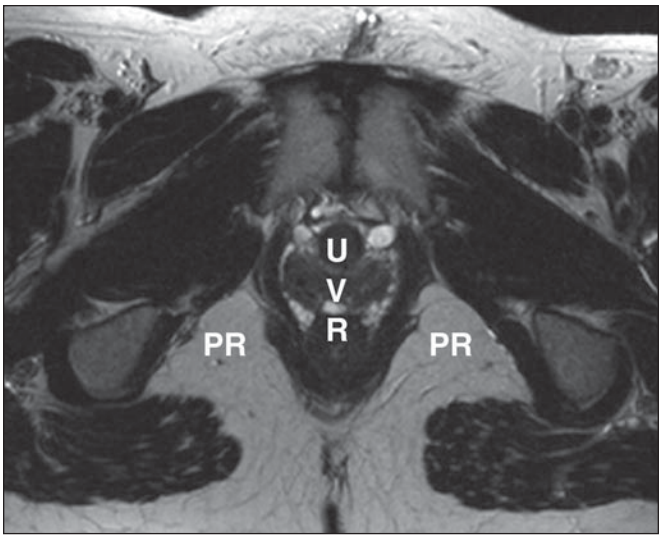

Fig. 3—22-year-old woman with mild symptoms of pelvic floor weakness. Axial T2-weighted turbo spin-echo MR image of pelvis shows normal butterfly shape of vagina (V), normal configuration, thickness and signal intensity of puborectalis muscle (PR), normal rectum (R), normal urethra (U), and adjacent normal periurethral ligaments.

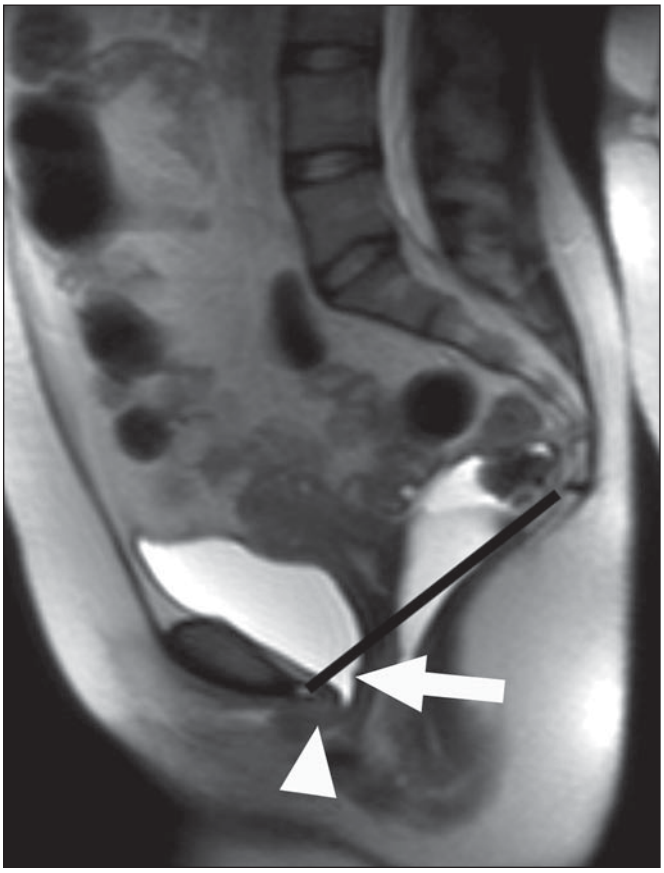

Fig. 4—33-year-old woman with severe urinary incontinence. Sagittal HASTE MR image of pelvis at strain shows cystocele (*arrow*) and abnormal urethra hypermobility, in which urethra assumes horizontal orientation (*arrowhead*). Also note abnormal position of bladder neck below pubococcygeal line. Mild inferior descent of rectum at strain is within normal limits.

ligaments of the female urethra by Macura et al. [25] using high-resolution MRI and an endourethral MR coil, three groups of ligaments supporting the female urethra were described: the periurethral ligaments arising from the puborectalis muscle and coursing ventral to the urethra, the paraurethral ligaments arising from the lateral wall of the urethra to the periurethral ligaments, and the pubourethral ligaments (Fig. 4). This network of ligaments and the anterior vaginal wall provide a hammocklike support to the urethra; together with the pelvic diaphragm, which elevates the urinary bladder and elongates the urethra, these support mechanisms play an important role in maintaining urinary continence in women [26]. Many studies have shown that disruption of this hammocklike support structure is closely related to the development of stress urinary incontinence in women [27–30].

Yang et al. [22] reported that the normal vertical distance of the bladder neck at strain should be less than 1 cm from the pubococcygeal line. The distal two thirds of the urethra is inseparable from the anterior vaginal wall. In patients with stress urinary incontinence, the support from the anterior vaginal wall is diminished; increased intraabdominal pressure results in descent of the bladder neck below the pubococcygeal line and prolapse of the urinary bladder through the anterior vaginal wall, resulting in a cystocele. Because the bladder neck and proximal urethra are mobile, descent of the bladder neck during strain may result in clockwise rotational descent of the bladder neck and proximal urethra. When the proximal urethra rotates more than 30°, urethral hypermobility results and can cause kinking of the proximal urethra that may mask stress urinary incontinence [31]. In a study by Kim et al. [9], distortion of the periurethral and paraurethral ligaments was frequently noted in patients with stress urinary incontinence, suggesting that a defect of connection between the urethra and the puborectalis sling is one of the principal causes of urethral hypermobility.

The normal butterfly shape of the vagina may also be altered by weakening of the paravaginal ligaments. The vagina may have a flattened appearance because the vaginal wall will be displaced posteriorly as a result of loss of paravaginal attachments. The disruption to the paravaginal ligaments will weaken support to the urethra because the middle and distal thirds of the urethra are closely related to and supported by the anterior vaginal wall. The loss of the normal shape of the vagina is therefore a good indication of paravaginal tears in patients with urinary incontinence. This information will be relevant to the surgeon because repair of the cystocele alone will not be sufficient, and fascial repair may also be necessary [32, 33].

Middle Compartment Prolapse

The middle compartment of the pelvic floor consists of the reproductive organs, the uterus, the cervix, and the vagina. Vaginal support in the pelvis has been described by

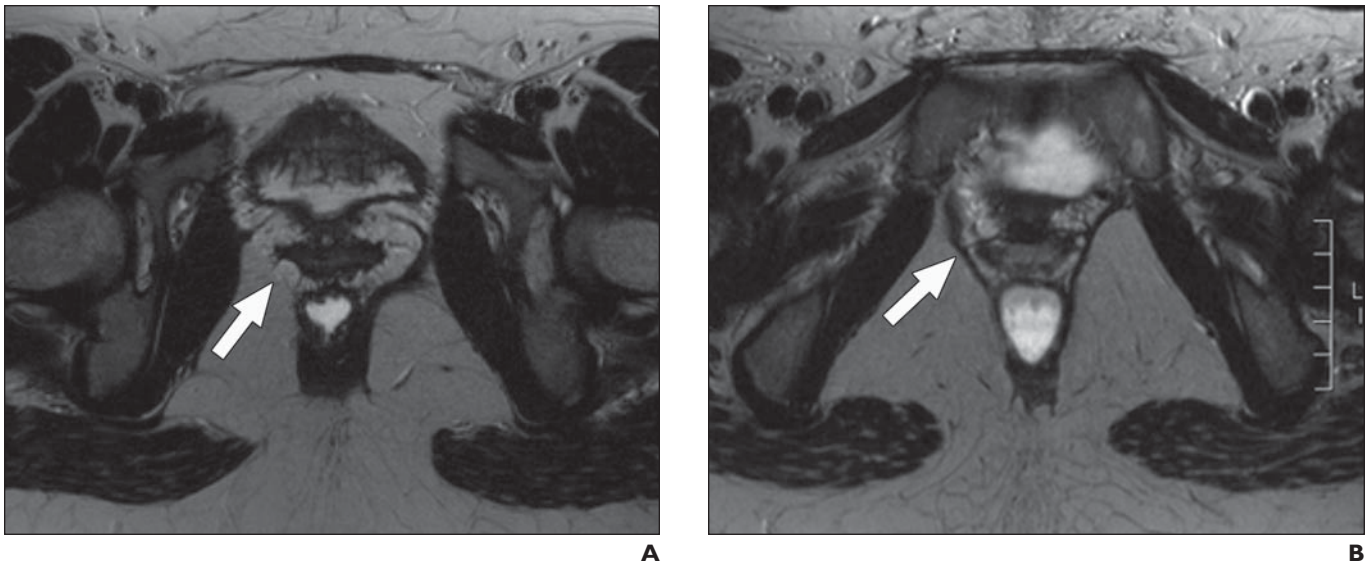

Fig. 5—Axial T2-weighted turbo spin-echo MR images of pelvis in two patients with symptoms of pelvic floor dysfunction.
A, 21-year-old woman with symptoms of defecatory dysfunction. Note complete tear of right puborectalis muscle (*arrow*) and loss of normal butterfly shape of vagina.
B, 36-year-old woman with symptoms of defecatory dysfunction. Note asymmetric appearance of puborectalis muscles. Right puborectalis muscle (*arrow*) shows slight ballooning, has convex morphology, and is torn anteriorly at insertion to pubis.

DeLancey [28] as having three levels of support. The cephalic 2- to 3-cm portion of the vagina, described as level 1, is suspended from the pelvic side wall by the parametrium and paracolpium, which are condensations of the endopelvic fascia. Level 3 is described as the level that starts at the hymen ring and extends 2–3 cm cephalad to it, and level 2 is between levels 1 and 3. Level 2 of the vagina is attached to the arcus tendineus, although level 3 is directly fused anteriorly to the urethra, laterally to the levator ani muscles, and posteriorly to the perineal body, rather than being attached to or suspended from the pelvic walls. Note that the distal third of the vagina has a different embryologic origin from the proximal two thirds of the vagina.

Prolapse of the middle compartment in patients who have undergone hysterectomy is also termed "apical prolapse" because of the prolapse of the vagina apex. When the patient has had a hysterectomy, support to the vaginal apex is provided by the paracolpium, and the vaginal apex should remain at least 1 cm above the pubococcygeal line at strain [22]. Damage to the paracolpium can then result in apical prolapse.

Although loss of the normal butterfly shape of the vagina is widely described as a sign of disruption of the paravaginal ligaments, loss of the normal shape of the vagina on MRI can also be seen in nulliparous asymptomatic women and in the absence of relevant clinical symptoms; therefore, the diagnosis of weakening of vaginal support should not be made based on vaginal shape alone [34].

The parametrium, consisting of the uterosacral and cardinal ligaments, suspends the uterus and cervix from the pelvic side walls. On midsagittal MR images, descent of the

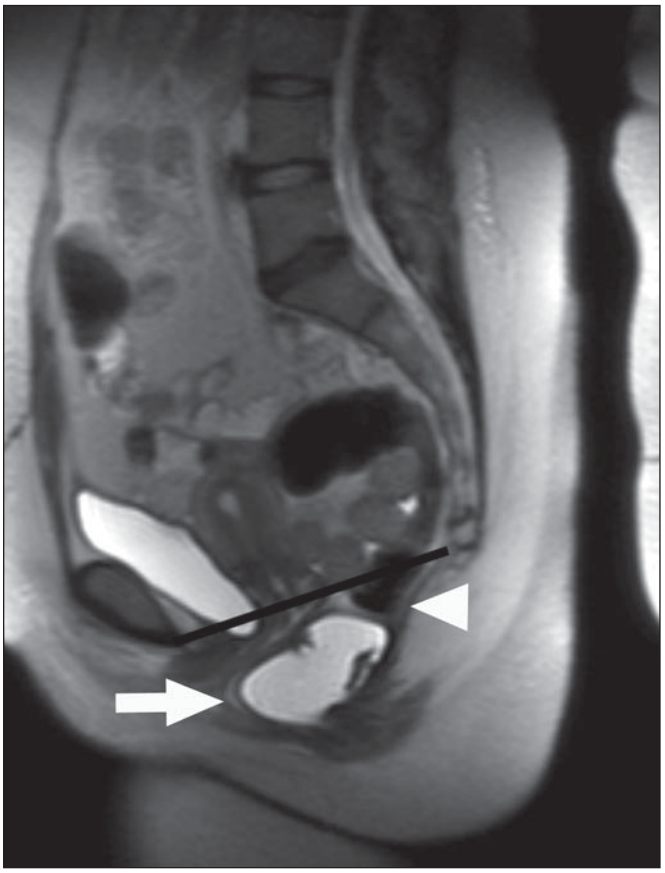

Fig. 6—36-year-old woman with symptoms of rectal prolapse. Sagittal HASTE MR image of pelvis at strain shows large rectocele (*arrow*) and abnormal caudal angulation of levator plate (*arrowhead*), indicating significant weakness of posterior compartment of pelvic floor.

uterus in addition to descent of the cervix and vagina usually suggests disruption of the uterosacral or cardinal ligaments. The H and M lines may be elongated. On axial images, the transverse dimension of the levator hiatus may be widened, the levator muscles may be asymmetric and assume a convex morphology, and the vagina may also be flattened or lose the symmetric butterfly shape (Fig. 5). The size of the urogenital hiatus in the levator muscles, a measurement that is determined clinically by physical examination, has been found to be larger in patients with pelvic organ prolapse [35]. A fibroid in the uterus may prevent descent of the uterus and cause underestimation of the true degree of pelvic floor dysfunction and supporting fascial damage. In severe cases, procidentia results and the entire uterus prolapses and lies outside the introitus.

Posterior Compartment Prolapse

The distal vagina is fused with the perineal body, which separates the vagina from the rectum. The perineal body is an important anchoring structure for the muscles and ligaments of the urogenital diaphragm. The rectovaginal fascia, condensation of the endopelvic fascia that attaches to the perineal body, also provides a support diaphragm, preventing posterior prolapse. One of the muscles of the levator ani, the iliococcygeus muscle, is a horizontally oriented sheet of muscle that, together with the rectovaginal fascia, forms a diaphragm that provides support to the pelvic organs, especially those in the posterior compartment. The puborectalis muscle, by forming a U-shaped sling between the pubis and the anus, acts to tighten the urogenital hiatus and keep the pelvic organs in position. The perineal body may be damaged by episiotomy during vaginal childbirth; separation of the perineal body or disruption of the rectovaginal fascia or the iliococcygeus muscle may allow the bowel and peritoneal contents to protrude inferiorly through the posterior vaginal wall, causing posterior prolapse.

The levator plate, the midline raphe of the iliococcygeus muscle, is easily identified on the midsagittal image of the dynamic MR examination; it should remain parallel to the pubococcygeal line in normal individuals [36]. Caudal angulation of the levator plate on the midsagittal MR image by more than 10° with respect to the pubococcygeal line is a sign of pelvic floor weakness [33].

The most common cause of posterior vaginal bulge is anterior rectocele, caused by herniation of the anterior wall of the rectum into the posterior vaginal wall as a result of weakness in the rectovaginal fascia. On the midsagittal image of the dynamic MR examination, rectocele is identified by a rectal bulge of more than 3 cm, which is the distance measured between the anal canal and the tip of the rectocele [37] (Fig. 6). Because an anterior rectal bulge of up to 3 cm may also occur in women without defecatory dysfunction, the patient's clinical symptoms, such as a feeling of incomplete defecation, should be considered in determining the significance of this finding on MR examination [38]. Although physical examination is sufficient for diagnosis of a simple anterior rectocele, it is unreliable in assessing more complex posterior compartment prolapse such as an enterocele. In a study involving 300 women, enteroceles were revealed with dynamic cystoproctography in 111 subjects; 93 of these were missed on physical examination [39]. Moreover, it may be impossible to determine exactly which organ is causing the posterior vaginal bulge on physical examination. The superior soft-tissue contrast of MRI allows the posterior compartment to be seen in great detail, such as the hyperintense T2 signal of peritoneal fat in peritoneoceles, the hyperintense fluid-filled small-bowel loops in enteroceles, and the hyperintense gel-filled rectum or sigmoid colon in rectoceles or sigmoidoceles.

Prolapse of peritoneal contents is due to deficiency of the supporting ligaments and iliococcygeus muscle, resulting in widening of the rectovaginal space. In normal individuals, the rectovaginal space caudal to the upper third of the vagina is closely apposed [19]. Widening of this space will allow inferior herniation of the peritoneal fat, small bowel, sigmoid colon, and fluid into the pouch of Douglas. Prior hysterectomy may cause disruption of the rectovaginal fascia and increase the risk of enterocele formation [40]. A large enterocele may mask a coexisting cystocele or rectocele because of the tight space in the pelvic floor. Reduction of the enterocele may be required before assessment of the other compartments of the pelvic floor can be performed. Conversely, a persistently large rectocele or incomplete evacuation of the rectal contents in a large rectocele may also mask an enterocele or a cystocele [40]. Adequate evacuation of the rectal contents during the dynamic MR examination is required to completely assess the pelvic floor. With adequate evacuation of the rectal contents, intussusception of the rectum where the rectum invaginates distally toward the anal canal may occasionally be identified on dynamic supine MR images, although the study by Bertschinger et al. [16] found that all rectal intussusceptions identified on sitting MR defecography were missed on supine MR examinations.

Summary

It has been long known that women with symptoms of pelvic floor dysfunction frequently have involvement of multiple compartments. MRI of the pelvic floor allows simultaneous assessment of all three compartments of the pelvic floor before surgery in patients with pelvic floor dysfunction and patients in whom conservative management is unsuccessful. In so doing, MRI may reduce the risk of surgical failure and the recurrence or persistence of the debilitating symptoms after surgery.

The use of ultrafast T2-weighted sagittal MRI described in this article allows noninvasive dynamic imaging of the pelvic floor, providing anatomic and functional information that will be useful to urogynecologists and surgeons. In ad-

dition, the use of high-resolution axial T2-weighted sequences of the pelvis allows identification of torn muscles and ligaments in patients with pelvic floor dysfunction who require surgery. The use of the pubococcygeal and H and M reference lines in the interpretation of the MR images is a simple method of identifying pelvic organ descent. For complete assessment of the severity of pelvic organ prolapse, MRI findings should be correlated with the severity of the patient's clinical symptoms.

References

1. Wilson L, Brown JS, Shin GP, Luc KO, Subak LL. Annual direct cost of urinary incontinence. *Obstet Gynecol* 2001; 98:398–406
2. Thom D. Variation in estimates of urinary incontinence prevalence in the community: effects of differences in definition, population characteristics, and study type. *J Am Geriatr Soc* 1998; 46:473–478
3. Olsen Al, Smith VJ, Bergstrom JO, Colling JC, Clark AL. Epidemiology of surgically managed pelvic organ prolapse and urinary incontinence. *Obstet Gynecol* 1997; 89:501–506
4. Rowe JW, Beedine RW, Ford AB, et al. NIH consensus development panel: urinary incontinence in adults. *JAMA* 1989; 261:2685–2690
5. Hendrix SL, Clark A, Nygaard I, Aragaki A, Barnabei V, McTiernan A. Pelvic organ prolapse in the Women's Health Initiative: gravity and gravidity. *Am J Obstet Gynecol* 2002; 186:1160–1166
6. Delancey JO, Kearney R, Chou Q, Speights S, Binno S. The appearance of levator ani muscle abnormalities in magnetic resonance images after vaginal delivery. *Obstet Gynecol* 2003; 101:46–53
7. Buchsbaum GM, Chin M, Glantz C, Guzick D. Prevalence of urinary incontinence and associated risk factors in a cohort of nuns. *Obstet Gynecol* 2002; 100:226–229
8. Clark MH, Scott M, Vogt V, Benson JT. Monitoring pudendal nerve function during labor. *Obstet Gynecol* 2001; 97:637–639
9. Kim JK, Kim YJ, Choo MS, Cho KS. The urethra and its supporting structures in women with stress urinary incontinence: MR imaging using an endovaginal coil. *AJR* 2003; 180:1037–1044
10. Kelvin FM, Hale DS, Maglinte DD, Patten BJ, Benson JT. Female pelvic organ prolapse: diagnostic contribution of dynamic cystoproctography and comparison with physical examination. *AJR* 1999; 173:31–37
11. Gonzalez-Argente FX, Jain A, Nogueras JJ, Davila GW, Weiss EG, Wexner SD. Prevalence and severity of urinary incontinence and pelvic genital prolapse in females with anal incontinence or rectal prolapse. .*Dis Colon Rectum* 2001; 44:920–926
12. Ng CS, Rackley RR, Appell RA. Incidence of concomitant procedures for pelvic organ prolapse and reconstruction in women who undergo surgery for stress urinary incontinence. *Urology* 2001; 57:911–913
13. Maglinte DD, Kelvin FM, Fitzgerald K, Hale DS, Benson JT. Association of compartment defects in pelvic floor dysfunction. *AJR* 1999; 172:439–444
14. Hetzer FH, Andreisek G, Tsagari C, Sahrbacher U, Weishaupt D. MR defecography in patients with fecal incontinence: imaging findings and their effect on surgical management. *Radiology* 2006; 240:449–457
15. Martin DR, Salman K, Wilmot CC, Galloway NT. MR imaging evaluation of the pelvic floor for the assessment of vaginal prolapse and urinary incontinence. *Magn Reson Imaging Clin N Am* 2006;14:523–535
16. Bertschinger KM, Hetzer FH, Roos JE, Treiber K, Marincek B, Hilfiker PR. Dynamic MR imaging of the pelvic floor performed with patient sitting in an open-magnet unit versus with patient supine in a closed-magnet unit. *Radiology* 2002; 223:501–508
17. Fielding JR, Griffiths DJ, Versi E, Mulkern RV, Tee MLT, Jolesz FA. MR imaging of pelvic floor continence mechanisms in the supine and sitting positions. *AJR* 1998; 171:1607–1610
18. Grousse AE, Barbaric ZL, Safir MH, Madjar S, Marumoto AK, Raz S. Dynamic half-Fourier acquisition, single-shot turbo spin-echo magnetic resonance imaging for evaluating the female pelvis. *J Urol* 2000; 164:1606–1613
19. Lienermann A, Anthuber C, Baron A, Reiser M. Diagnosing enteroceles using dynamic magnetic resonance imaging. *Dis Colon Rectum* 2000; 43:205–212
20. Kelvin FM, Maglinte DD, Hale DS, Benson JT. Female pelvic organ prolapse: a comparison of triphasic dynamic MR imaging and triphasic fluoroscopic cystocolpoproctography. *AJR* 2000; 174:81–88
21. Kruyt RH, Delemarre JBVM, Doornbos J, Vogel HJ. Normal anorectum: dynamic MR imaging anatomy. *Radiology* 1991; 179:159–163
22. Yang A, Mostwin JL, Rosenheim NB, Zerhouni EA. Pelvic floor descent in women: dynamic evaluation with fast MR imaging and cinematic display. *Radiology* 1991; 179:25–33
23. Lienermann A, Anthuber C, Baron A, Kohz P, Reiser M. Dynamic MR colpocystography assessing pelvic floor descent. *Eur Radiol* 1997; 7:1309–1317
24. Comiter CV, Vasavada SP, Barbaric ZL, Gousse AE, Raz S. Grading pelvic floor prolapse and pelvic floor relaxation using dynamic magnetic resonance imaging. *Urology* 1999; 54:454–457
25. Macura KJ, Genadry RR, Bluemke DA. MR imaging of the female urethra and supporting ligaments in assessment of urinary incontinence: spectrum of abnormalities. *RadioGraphics* 2006; 26:1135–1149
26. Oelrich T. The striated urogenital sphincter muscle in the female. *Anat Rec* 1983; 205:223–232
27. DeLancey JO. Structural support of the urethra as it relates to stress urinary incontinence: the hammock hypothesis. *Am J Obstet Gynecol* 1994; 170:1713–1723
28. DeLancey JO. Correlative study of paraurethral anatomy. *Obstet Gynecol* 1986; 68:91–97
29. Cruikshank SH, Kovac SR. The functional anatomy of the urethra: role of the pubourethral ligaments. *Am J Obstet Gynecol* 1997; 176:1200–1205
30. Klutke C, Golomb J, Barbaric Z, Raz S. The anatomy of stress incontinence: magnetic resonance imaging of the female bladder neck and urethra. *J Urol* 1990; 143:563–566
31. Bergman A, McCarthy TA, Ballard CA, Yanai J. Role of the Q-tip test in evaluating stress urinary incontinence. *J Reprod Med* 1987; 32:273–275
32. Stoker J, Halligan S, Bartram CI. Pelvic floor imaging. *Radiology* 2001; 218:621–641
33. Fielding JR. MR imaging of pelvic floor relaxation. *Radiol Clin N Am* 2003; 41:747–756
34. Macura KJ. Magnetic resonance imaging of pelvic floor defects in women. *Top Magn Reson Imaging* 2006; 17:417–426
35. Delancey JO, Hurd WW. Size of the urogenital hiatus in the levator ani muscles in normal women and women with pelvic organ prolapse. *Obstet Gynecol* 1998; 91:364–368
36. Ozasa H, Mori T, Togashi K. Study of uterine prolapse by magnetic resonance imaging: topographical changes involving the levator ani muscle and the vagina. *Gynecol Obstet Invest* 1992; 34:43–48
37. Yshioka K, Matsui Y, Yamado O, et al. Physiologic and anatomic assessment of patients with rectocele. *Dis Colon Rectum* 1991; 34:704–708
38. Felt-Bersma RJ, Cuesta MA. Rectal prolapse, rectal intussusception, rectocele, and solitary rectal ulcer syndrome. *Gastroenterol Clin North Am* 2001; 30:199–222
39. Kelvin FM, Maglinte DDT, Hornback JA, Benson JT. Pelvic prolapse: assessment with evacuation proctography (defecography). *Radiology* 1992; 184:547–551
40. Mellgren A, Johansson C, Dolk A, et al. Enterocele demonstrated by defaecography is associated with other pelvic floor disorders. *Int J Colorectal Dis* 1994; 9:121–124
41. Cardozo L. *Urogynecology*. New York, NY: Churchill-Livingstone, 1997: 325–326

FOR YOUR INFORMATION

The reader's attention is directed to the SAM for this article, which appears on the following pages.

MRI of Pelvic Floor Dysfunction: *Self-Assessment Module*

Yan Mee Law[1,2] and Julia R. Fielding[2]

ABSTRACT

Objective

The educational objectives of this continuing medical education activity are for the reader to exercise, self-assess, and improve skills in diagnostic radiology with regard to the interpretation of MRI of the female pelvis in the evaluation of pelvic floor dysfunction, and to improve familiarity with the clinical features of female pelvic floor dysfunction.

Conclusion

The articles in this activity review the anatomy and etiology of pelvic floor weakness in women and discuss the role of MRI in the assessment of female pelvic floor dysfunction.

INTRODUCTION

This self-assessment module on MRI of pelvic floor dysfunction has an educational component and a self-assessment component. The educational component consists of two required articles that the participant should read and three recommended articles that may provide additional information and perspective. The self-assessment component consists of 10 multiple-choice questions with solutions. All of these materials are available on the ARRS Website (www.arrs.org). To claim CME and SAM credit, each participant must enter his or her responses to the questions online.

EDUCATIONAL OBJECTIVES

By completing this educational activity, the participant will:

A. Exercise, self-assess, and improve his or her understanding of the imaging features of pelvic floor dysfunction.

B. Exercise, self-assess, and improve his or her understanding of the clinical features of pelvic floor dysfunction.

REQUIRED READING

1. Law YM, Fielding JR. MRI of pelvic floor dysfunction: review. *AJR* 2008; 191[suppl]:S00–S00
2. Macura KJ. Magnetic resonance imaging of pelvic floor defects in women. *Top Magn Reson Imaging* 2006; 17:417–426

RECOMMENDED READING

1. Hetzer FH, Andreisek G, Tsagari C, Sahrbacher U, Weishaupt D. MR defecography in patients with fecal incontinence: imaging findings and their effect on surgical management. *Radiology* 2006; 240:449–457
2. Martin DR, Salman K, Wilmot CC, Galloway NT. MR imaging evaluation of the pelvic floor for the assessment of vaginal prolapse and urinary incontinence. *Magn Reson Imaging Clin N Am* 2006; 14:523–535
3. Macura KJ, Genadry RR, Bluemke DA. MR imaging of the female urethra and supporting ligaments in assessment of urinary incontinence: spectrum of abnormalities. *RadioGraphics* 2006; 26:1135–1149

INSTRUCTIONS

1. Complete the required reading.
2. Visit www.arrs.org and select Publications/Journals/SAM Articles from the left-hand menu bar.
3. Using your member login, order the online SAM as directed.
4. Follow the online instructions for entering your responses to the self-assessment questions and complete the test by answering the questions online.

Keywords: cystocele, MRI, pelvic floor dysfunction, rectocele

DOI:10.2214/AJR.07.7113

Received July 17, 2008; accepted without revision July 17, 2008.

[1]Department of Diagnostic Radiology, Singapore General Hospital, Outram Rd., Singapore 169608, Republic of Singapore. Address correspondence to Y. M. Law (law.yan.mee@sgh.com.sg).

[2]Department of Radiology, The University of North Carolina at Chapel Hill, Chapel Hill, NC.

AJR 2008;191:SXX–SXX 0361–803X/08/1916–SXX

QUESTION 1

Regarding the risk factors for pelvic floor dysfunction, which one of the following statements is FALSE?

A. Age, sex, and vaginal parity are established risk factors for pelvic floor dysfunction.
B. Nulliparous women are spared pelvic floor dysfunction.
C. Vaginal delivery results in neuromuscular damage that can occur much earlier than the onset of pelvic floor dysfunction.
D. With advanced age, hypoestrogenemia during menopause results in progression of symptoms of pelvic floor dysfunction.
E. Not all women who undergo vaginal delivery suffer from pelvic floor dysfunction.

QUESTION 2

Which of the following statements regarding urinary incontinence is FALSE?

A. Stress urinary incontinence is involuntary and results from an increase in intraabdominal pressure.
B. Stress urinary incontinence is related to urethral sphincter deficiency.
C. Compared with stress and urge urinary incontinence, overflow urinary incontinence is less common in women.
D. Overflow urinary incontinence never occurs in bladder outlet obstruction.
E. Urge urinary incontinence results in leakage of a large volume of urine when the patient experiences a sudden urge to void.

QUESTION 3

Which of the following statements regarding the endopelvic fascia and perineal body is TRUE?

A. The endopelvic fascia lies deep in relation to the levator ani.
B. The parametrium and paracolpium support the rectum and small bowel.
C. The condensations of the endopelvic fascia are well visualized on conventional MRI without any need for an endovaginal coil.
D. The perineal body separates the rectum from the vagina.
E. The iliococcygeus muscle of the levator ani arises from the endopelvic fascia and attaches to the pelvic side wall.

QUESTION 4

Which structure plays the most important role in apposing the orifices of the pelvic floor and elevating the bladder neck?

A. The levator plate.
B. The iliococcygeus muscle.
C. The puborectalis muscle.
D. The symphysis pubis.
E. The rectovaginal fascia.

QUESTION 5

Which one of the following statements regarding MRI of pelvic floor dysfunction in women is FALSE?

A. Sitting MR defecography performed on a 0.5-T MR system is superior to conventional dynamic supine MRI for the depiction of clinically relevant bladder descents and rectoceles.
B. Instilling a small volume of intraluminal ultrasonic gel that has a hyperintense T2 signal into the vagina and rectum allows improved visualization of the pelvic viscera.
C. Fat saturation is conventionally not applied in dynamic supine MRI of the pelvic floor.
D. The conventional sequences used in dynamic MRI of the pelvic floor are the rapid T2-weighted sequences such as single-shot fast spin echo or HASTE.
E. The pelvic floor muscles and the levator plate are well visualized on conventional MRI.

QUESTION 6

In interpreting the MRI findings of women with pelvic floor dysfunction, which one of the following statements is TRUE?

A. Caudal angulation of the levator plate by 5° with respect to the pubococcygeal line is a significant sign of pelvic floor weakness.
B. The pubococcygeal line extends from the superior pubic ramus to the last sacrococcygeal joint.
C. The H and M reference lines are shortened in patients with significant pelvic floor dysfunction.
D. The bladder neck at strain should be less than 3 cm from the pubococcygeal line in patients with normal anatomy.
E. The H and M reference lines used in grading the extent of pelvic organ descent are indicative of the anteroposterior width of the levator hiatus and descent of the levator hiatus from the pubococcygeal line, respectively.

QUESTION 7

Regarding the vagina, which one of the following statements is TRUE?

A. The distal two thirds of the vagina have a different embryologic origin from the proximal one third.
B. The loss of the normal butterfly shape of the vagina is a significant sign in itself and is a strong indication of weakening of vaginal support.
C. There is normally a gap in the rectovaginal fascia caudal to the upper third of the vagina.
D. In patients who have had a hysterectomy, the normal vaginal apex routinely descends 3 cm below the pubococcygeal line at strain.
E. The distal one third of the vagina is not suspended from the pelvic side wall by the paravaginal ligaments.

QUESTION 8

In posterior compartment prolapse, which one of the following statements is TRUE?

A. Intussusception of the rectum where the rectum invaginates distally toward the anal canal can be reliably identified when the examination is performed without evacuation of the rectal contents.
B. The most common cause of posterior vaginal bulge is an enterocele.
C. The rectovaginal fascia attaches to the perineal body and acts as an important support structure that prevents posterior compartment prolapse.
D. A rectocele on dynamic supine MR examination is always associated with urinary incontinence.
E. An anterior rectal bulge of 1 cm is abnormal and is diagnostic of a rectocele.

QUESTION 9

In anterior compartment prolapse, which one of the following statements is TRUE?

A. Urinary incontinence can be masked by urethral hypermobility due to kinking of the urethra.
B. A video urodynamic study is not necessary.
C. Urinary incontinence never occurs in the absence of a cystocele.
D. Elevation of the bladder neck by the iliococcygeus muscle is important in maintaining urinary continence.
E. Surgery is the first line of treatment for patients with urinary incontinence because they likely have complex multicompartment pelvic floor dysfunction.

QUESTION 10

Which of the following statements regarding pelvic floor dysfunction is TRUE?

A. Dynamic MRI of the pelvic floor provides detailed anatomic information that is useful in preoperative planning of patients with pelvic floor dysfunction.
B. MRI of pelvic floor dysfunction is performed routinely for all patients with pelvic floor dysfunction, regardless of severity.
C. Pelvic floor dysfunction usually involves only a single compartment; involvement of multiple compartments is rare.
D. Any descent of the bladder neck at strain is always abnormal and is a sign of pelvic floor weakness.
E. Procidentia is a form of posterior compartment prolapse.

Solution to Question 1

The consensus statement from the National Institutes of Health concluded that age, sex, and vaginal parity are established risk factors for pelvic floor dysfunction [1]. Option A is not the best response. Not all women who have undergone vaginal delivery develop pelvic floor dysfunction [2], and not all nulliparous women are free from pelvic floor dysfunction [3]. Electromyography studies have shown that vaginal delivery causes neuromuscular damage to the pelvic floor well before the onset of pelvic floor dysfunction [4]. Option C is not the best response. Hypoestrogenemia and menopause can result in progressive weakening of the muscles, ligaments, and fascia that support the pelvic floor, resulting in progression of symptoms with advancing age. Option D is not the best response. Although epidemiologic evidence supports the relation between vaginal delivery and pelvic floor dysfunction, not all women who undergo vaginal delivery develop pelvic floor dysfunction, and not all nulliparous women are free from pelvic floor dysfunction. Option E is not the best response. As explained above [1], nulliparous women are therefore not spared from pelvic floor dysfunction. **Option B, which is false, is the best response.**

Solution to Question 2

Stress urinary incontinence is the involuntary loss of urine due to an increase in intraabdominal pressure such as coughing and sneezing; it is related to urethral sphincter deficiency. Options A and B are not the best responses. Urge incontinence and overflow urinary incontinence are related to bladder abnormalities. Urge urinary incontinence is due to detrusor instability or damage to the nervous system supplying the urinary bladder such as in multiple sclerosis, stroke, or pelvic injury; it results in leakage of a large amount of urine

when the patient experiences a sudden urge to urinate. Option E is not the best response. In overflow urinary incontinence, leakage of a small amount of urine occurs when the urinary bladder is overdistended due to weakness of the bladder muscles in a neurogenic bladder or in chronic bladder outlet obstruction. Overflow incontinence is less common in women than in men. Option C is not the best response. Overflow incontinence occurs in chronic bladder outlet obstruction. **Option D, which is false, is the best response.**

Solution to Question 3

The endopelvic fascia is the most superior layer of the pelvic floor and covers the levator ani and the pelvic viscera in a continuous sheet. Option A is not the best response. The endopelvic fascia attaches the cervix and vagina to the pelvic side wall via the elastic condensations known as the parametrium and the paracolpium, respectively. These fascial condensations are not well visualized on conventional MRI; their defects may be inferred indirectly through secondary findings. Option B is not the best response. These ligaments may be better visualized with an endovaginal coil, which, if placed near the target organ, provides more detailed visualization of fine structures. Option C is not the best response. The iliococcygeus muscle has a horizontal orientation, arises from the external anal sphincter, and fans out laterally, attaching to the arcus tendineus. The iliococcygeus muscle does not arise from the endopelvic fascia. Option E is not the best response. The perineal body lies inferior to the levator ani muscles and separates the vagina and rectum. **Option D, which is the only true answer, is the best response.**

Solution to Question 4

The puborectalis muscle forms a sling around the rectum and plays an important role in apposing the orifices of the pelvic floor as well as elevating the bladder neck and compressing it against the pubic symphysis. Option C is the best response. The horizontally oriented iliococcygeus muscle, which arises from the external anal sphincter and fans out laterally, attaches to the arcus tendineus to act as an important physical barrier, preventing prolapse of the posterior compartment, which includes the rectum and the peritoneal contents. Option B is not the best response. The rectovaginal fascia is part of the endopelvic fascia that forms a supportive layer between the rectum and the vagina, preventing posterior compartment prolapse. Option E is not the best response. The symphysis pubis is a bony structure where the levator ani muscles attach anteriorly. Option D is not the best response. The levator plate is a firm raphe anterior to the coccyx from condensation of the iliococcygeus muscle. Option A is not the best response.

Solution to Question 5

The superior soft-tissue contrast of MRI allows direct visualization of the pelvic floor musculature and levator plate. Option E is not the best response. Rapid T2-weighted sequences such as single-shot fast spin echo or HASTE are the typical sequences described for dynamic MRI of the pelvic floor. Option D is not the best response. Fat saturation is generally not applied to MR sequences of the pelvic floor because the hyperintense signal of fat in the pelvis provides good contrast against the hypointense signal of the adjacent muscles, fascia, and pubic bones. Option C is not the best response. A small volume of intraluminal ultrasonic gel that has a hyperintense T2 signal may be instilled into the vagina and rectum to improve pelvic viscera visualization. Option B is not the best response. The presence of endoluminal gel in the rectum may improve straining efforts and increase the conspicuity of pelvic organ prolapse and visceral descent. Although MRI defecography performed in a 0.5-T open MR system with the patient in a sitting position more closely resembles the physiologic state, studies have shown that it is not superior to dynamic supine MRI for depiction of clinically relevant bladder descents and rectoceles [5, 6]. **Option A, which is not true, is the best response.**

Solution to Question 6

The level of the pelvic floor in dynamic pelvic floor MRI is demarcated radiologically on the midsagittal image by the pubococcygeal line, which extends from the most inferior portion of the pubic symphysis to the last sacrococcygeal joint [7]. Option B is not the best response. The H and M reference lines are used in pelvic floor imaging to identify pelvic organ descent [8]. The H and M lines are lengthened in patients with significant pelvic floor dysfunction. Option C is not the best response. The H line measures the distance from the inferior symphysis pubis to the posterior anorectal junction on the midsagittal image and is indicative of the anteroposterior width of the levator hiatus. The M line is drawn perpendicular from the pubococcygeal line to the most distal aspect of the H line and is indicative of the descent of the levator hiatus from the pubococcygeal line. The presence of significant pelvic floor prolapse will result in sloping of the levator plate and increasing length of the H and M lines. The levator plate should remain parallel to the pubococcygeal line in normal subjects [9]. **Option E is the best response.** Caudal angulation of the levator plate on the midsagittal MR image by more than 10° with respect to the pubococcygeal line is a sign of pelvic floor weakness [10]. Option A is not the best response. The normal vertical distance of the bladder neck at strain should be less than 1 cm from the pubococcygeal line [7]. Option D is not the best response.

Solution to Question 7

The distal one third of the vagina has a different embryologic origin from the proximal two thirds. Option A is not the best response. It is directly attached to its surrounding structures; anteriorly to the urethra, posteriorly to the perineal body, and laterally with the levator ani, and is not

suspended from the pelvic side wall by the paravaginal ligaments. **Option E is the best response.** Although loss of the normal butterfly shape of the vagina on MRI is a sign of weakness of the paravaginal ligaments, it can also be seen in nulliparous asymptomatic women and in the absence of relevant clinical symptoms. The diagnosis of weakening of the vaginal support should not be made on the basis of vaginal shape alone [11]. Option B is not the best response. In patients with normal anatomy, the rectovaginal fascia caudal to the upper third of the vagina is closely apposed [12]. Option C is not the best response. Posterior compartment prolapse is due to deficiency of the supporting ligaments and muscles of the pouch of Douglas, resulting in widening of the rectovaginal space. When the patient has had a prior hysterectomy, support to the vaginal apex is provided by the paracolpium, and the vaginal apex should remain at least 1 cm above the pubococcygeal line at strain. Option D is not the best response.

Solution to Question 8

On dynamic MRI of the pelvic floor, a rectocele is identified by an anterior rectal bulge of more than 3 cm, which is the distance measured between the anal canal and the tip of the rectocele [13]. Option E is not the best response. An anterior rectal bulge of up to 3 cm may also occur in asymptomatic women without defecatory dysfunction and may not represent pelvic floor dysfunction [14]. Rectocele may be associated with defecatory dysfunction and is not always associated with urinary incontinence. Option D is not the best response. The most common cause of posterior vaginal bulge is an anterior rectocele caused by herniation of the anterior wall of the rectum into the posterior vaginal wall due to weakness in the rectovaginal fascia. Option B is not the best response. The rectovaginal fascia is the condensation of the endopelvic fascia that attaches to the perineal body, acting as a support diaphragm and preventing posterior prolapse. **Option C is the best response.** Intussusception of the rectum where it invaginates distally toward the anal canal may not be reliably identified on dynamic supine MRI. The study by Bertschinger et al. [5] found that all rectal intussusceptions identified on sitting MR defecography were missed on supine MR examinations [5]. Intussusception of the rectum may occasionally be identified on dynamic supine examinations when the rectal contents have been adequately evacuated. Option A is not the best response.

Solution to Question 9

Urethral hypermobility is due to rotational descent rather than vertical descent of the mobile bladder neck and proximal urethra. With a maximum Valsalva maneuver, descent of the mobile bladder neck during strain may result in clockwise rotational descent of the bladder neck and proximal urethra. When the proximal urethra rotates more than 30°, urethral hypermobility results and can cause kinking of the proximal urethra, which may mask stress urinary incontinence because it prevents leakage of urine from being detected clinically [15]. **Option A is the best response.** Most patients with mild symptoms of urinary continence benefit from a thorough physical examination and urodynamic study, which are important in assessing patients with urinary incontinence. Option B is not the best response. Urinary incontinence can occur without cystocele formation. Option C is not the best response. The puborectalis component of the levator ani and not the iliococcygeus muscle plays an important role in elevating the bladder neck and compressing it against the pubic symphysis, helping to maintain urinary continence. Option D is not the best response. Surgery is indicated only when conservative measures such as pelvic floor exercise, use of a pessary, and lifestyle modifications are ineffective in patients with urinary incontinence. Option E is not the best response.

Solution to Question 10

Several studies have shown that patients with urinary incontinence have coexisting pelvic organ prolapse in the other two compartments, requiring surgical repair [16–18]. It is therefore not uncommon that patients with pelvic floor dysfunction have involvement of multiple compartments. Option C is not the best response. MRI of pelvic floor dysfunction is not indicated in patients with mild symptoms of pelvic floor dysfunction such as a small cystocele or mild urinary incontinence. Option B is not the best response. However, MRI is an invaluable tool in preoperative planning in patients with severe pelvic floor dysfunction who require surgical repair. **Option A is the best response.** Mild descent of the bladder neck of less than 1 cm is seen in normal patients and is not a sign of pelvic floor dysfunction [7]. Option D is not the best response. Procidentia refers to prolapse of the uterus beyond the introitus and is a severe form of middle compartment prolapse. Option E is not the best response.

References

1. Rowe JW, Beedine RW, Ford AB, et al. NIH consensus development panel: urinary incontinence in adults. *JAMA* 1989; 261:2685–2690
2. Delancey JO, Kearney R, Chou Q, Speights S, Binno S. The appearance of levator ani muscle abnormalities in magnetic resonance images after vaginal delivery. *Obstet Gynecol* 2003; 101:46–53
3. Buchsbaum GM, Chin M, Glantz C, Guzick D. Prevalence of urinary incontinence and associated risk factors in a cohort of nuns. *Obstet Gynecol* 2002; 100:226–229
4. Clark MH, Scott M, Vogt V, Benson JT. Monitoring pudendal nerve function during labor. *Obstet Gynecol* 2001; 97:637–639
5. Bertschinger KM, Hetzer FH, Roos JE, Treiber K, Marincek B, Hilfiker PR. Dynamic MR imaging of the pelvic floor performed with patient sitting in an open-magnet unit versus with patient supine in a closed-magnet unit. *Radiology* 2002; 223:501–508
6. Fielding JR, Griffiths DJ, Versi E, Mulkern RV, Tee MLT, Jolesz FA. MR imaging of pelvic floor continence mechanisms in the supine and sitting positions. *AJR* 1998; 171:1607–1610
7. Yang A, Mostwin JL, Rosenheim NB, Zerhouni EA. Pelvic floor descent in women: dynamic evaluation with fast MR imaging and cinematic display. *Radiology* 1991: 179:25–33

8. Comiter CV, Vasavada SP, Barbaric ZL, Gousse AE, Raz S. Grading pelvic floor prolapse and pelvic floor relaxation using dynamic magnetic resonance imaging. *Urology* 1999; 54:454–457
9. Ozasa H, Mori T, Togashi K. Study of uterine prolapse by magnetic resonance imaging: topographical changes involving the levator ani muscle and the vagina. *Gynecol Obstet Invest* 1992; 34:43–48
10. Fielding JR. MR imaging of pelvic floor relaxation. *Radiol Clin N Am* 2003; 41:747–756
11. Macura KJ. Magnetic resonance imaging of pelvic floor defects in women. *Top Magn Reson Imaging* 2006; 17:417–426
12. Lienermann A, Anthuber C, Baron A, Reiser M. Diagnosing enteroceles using dynamic magnetic resonance imaging. *Dis Colon Rectum* 2000; 43:205–212
13. Yoshioka K, Matsui Y, Yamado O, et al. Physiologic and anatomic assessment of patients with rectocele. *Dis Colon Rectum* 1991; 34:704–708
14. Felt-Bersma RJ, Cuesta MA. Rectal prolapse, rectal intussusception, rectocele, and solitary rectal ulcer syndrome. *Gastroenterol Clin North Am* 2001; 30:199–222
15. Bergman A, McCarthy TA, Ballard CA, Yanai J. Role of the Q-tip test in evaluating stress urinary incontinence. *J Reprod Med* 1987; 32:273–275
16. Gonzalez-Argente FX, Jain A, Nogueras JJ, Davila GW, Weiss EG, Wexner SD. Prevalence and severity of urinary incontinence and pelvic genital prolapse in females with anal incontinence or rectal prolapse. *Dis Colon Rectum* 2001; 44:920–926
17. Ng CS, Rackley RR, Appell RA. Incidence of concomitant procedures for pelvic organ prolapse and reconstruction in women who undergo surgery for stress urinary incontinence. *Urology* 2001; 57:911–913
18. Maglinte DD, Kelvin FM, Fitzgerald K, Hale DS, Benson JT. Association of compartment defects in pelvic floor dysfunction. *AJR* 1999; 172:439–444

FOR YOUR INFORMATION

The reader's attention is directed to the review article pertaining to this SAM, which appears on the preceding pages.

Interpretation and Clinical Applications of Breast MRI: *Self-Assessment Module*

Linda Moy[1] and Cecilia L. Mercado

ABSTRACT

The educational objectives for this self-assessment module on the interpretation and clinical applications of breast MRI are for the participant to exercise, self-assess, and improve his or her understanding of the imaging and clinical features of cancer and other breast masses on MRI.

INTRODUCTION

This self-assessment module on breast MRI interpretation and clinical applications has an educational component and a self-assessment component. The educational component consists of four required articles that the participant should read. The self-assessment component consists of 10 multiple-choice questions with solutions. All of these materials are available on the ARRS Website (www.arrs.org). To claim CME and SAM credit, each participant must enter his or her responses to the questions online.

EDUCATIONAL OBJECTIVES

By completing this educational activity, the participant will:

A. Exercise, self-assess, and improve his or her understanding of the imaging and clinical features of breast masses on MRI.

B. Exercise, self-assess, and improve his or her understanding of the imaging and clinical features of breast cancer.

REQUIRED READING

1. Kuhl CK. The current status of breast MR imaging. Part 1. Choice of technique, image interpretation, diagnostic accuracy, and transfer to clinical practice. *Radiology* 2007; 244:356–378
2. Kuhl CK. Current status of breast MR imaging. Part 2. Clinical applications. *Radiology* 2007; 244:672–691
3. Liberman L, Morris EA, Dershaw DD, Abramson AF, Tan LK. MR imaging of the ipsilateral breast in women with percutaneously proven breast cancer. *AJR* 2003; 180:901–910
4. Lehman CD, Gatsonis C, Kuhl CK, et al. MRI evaluation of the contralateral breast in women with recently diagnosed breast cancer. *N Engl J Med* 2007; 356:1295–1303

INSTRUCTIONS

1. Complete the required reading.
2. Visit www.arrs.org and select Publications/Journals/SAM Articles from the left-hand menu bar.
3. Using your member login, order the online SAM as directed.
4. Follow the online instructions for entering your responses to the self-assessment questions and complete the test by answering the questions online.

Keywords: breast cancer, breast MRI

DOI:10.2214/AJR.07.7050

Received October 29, 2007; accepted after revision January 4, 2008.

[1]Both authors: Breast Imaging Center, New York University School of Medicine, 160 E 34th St., New York, NY 10016. Address correspondence to L. Moy (linda.moy@nyumc.org).

AJR 2008;191:SXX–SXX 0361–803X/08/1916–SXX

QUESTION 1

Concerning MRI for the staging of breast cancer, which of the following statements is FALSE?

A. MRI has a high sensitivity for the detection of multifocal disease.
B. MRI has a high sensitivity for the detection of multicentric disease.
C. MRI has a high sensitivity for the detection of contralateral disease.
D. MRI has a high sensitivity for the detection of metastatic lymph nodes.

QUESTION 2

All of the following are relative contraindications to breast conservation EXCEPT which one?

A. Extensive multicentric disease.
B. Extension of the tumor to the axillary lymph nodes.
C. Extension of the tumor to the chest wall.
D. Extension of the tumor to the areola.

QUESTION 3

Concerning the role of MRI in the evaluation of an inconclusive findings mammogram, which statement is TRUE?

A. There is no role for MRI in the evaluation of microcalcifications.
B. There is no role for MRI in the evaluation of focal asymmetry.
C. There is no role for MRI in the evaluation of an area of architectural distortion.
D. There is no role for MRI in the evaluation of a lesion seen on one view only.
E. There is no role for MRI in the evaluation of proteinaceous cysts.

QUESTION 4

Modifications in surgical management that may be indicated after breast MRI include all of the following EXCEPT which one?

A. Change treatment from breast conservation surgery to mastectomy.
B. Change treatment from sentinel lymph node dissection to full axillary node dissection.
C. Perform wider local excision than was originally planned.
D. Change treatment from conventional surgery followed by chemotherapy and radiation therapy to neoadjuvant chemotherapy.

QUESTION 5

The American Cancer Society recommends MRI screening in addition to mammography for women who have all of the following conditions EXCEPT:

A. They have a *BRCA1* or *BRCA2* mutation.
B. They have a first-degree relative with a *BRCA1* or *BRCA2* mutation.
C. They have a personal history of breast cancer.
D. Their lifetime risk of breast cancer has been scored at 20–25% or greater.
E. They had irradiation to the chest between the ages of 10 and 30 years.

QUESTION 6

Which statement is TRUE regarding women who present with isolated metastatic adenocarcinoma involving the axillary lymph nodes?

A. Occult cancers detected on MRI are large, usually greater than 3 cm.
B. MRI identifies the primary breast cancer in 50% of these women.
C. Traditional management is mastectomy if the primary breast cancer is not identified.
D. MRI is of limited value in staging breast cancer in this setting.

QUESTION 7

Concerning the role of MRI in monitoring response to neoadjuvant chemotherapy, which option is FALSE?

A. MRI can predict response to neoadjuvant chemotherapy after the second cycle has been completed.
B. The degree of underestimation of residual disease depends on the chemotherapy regimen.
C. MRI is superior to mammography, sonography, and clinical breast examination for measuring residual disease after neoadjuvant chemotherapy.
D. MRI can definitively exclude the presence of residual disease at the end of the course of chemotherapy.
E. A change in the enhancement kinetics suggests a response to chemotherapy.

QUESTION 8

Which statement is FALSE regarding breast MRI?

A. MRI is the most accurate imaging technique available for the local staging of breast cancer.
B. MRI correlates with histologic tumor size better than mammography and sonography.
C. Preoperative MRI may reduce the incidence of local recurrence.
D. MRI can detect residual disease in the immediate postoperative setting.
E. An enhancing scar 6 months after surgery and radiation therapy is highly suggestive of a local recurrence.

QUESTION 9

Which of the following is TRUE regarding evaluation of breast implants on MRI?

A. MRI allows the detection of breast cancers behind an implant.
B. MRI is indicated to evaluate rupture of a saline implant.
C. The MRI sign of complete intracapsular rupture is the "keyhole sign."
D. The MRI sign of incomplete intracapsular rupture is the "linguine sign."
E. MRI does not allow the detection of extracapsular rupture.

QUESTION 10

Concerning the role of MRI in a patient diagnosed with invasive lobular carcinoma, which statement is FALSE?

A. The sensitivity of MRI for invasive lobular carcinoma is higher than that achieved by mammography, sonography, or clinical breast examination.
B. Morphology is often masslike, and a typical invasive lobular carcinoma presents as an irregular or spiculated mass.
C. Preoperative MRI leads to a change of surgical management in 90% of invasive lobular carcinomas.
D. MRI gives the best estimate of lesion size compared with other imaging techniques.

Solution to Question 1

The demand for breast-conserving treatment has created pressure for preoperative definition of the extent of a cancer, which is not often elucidated by mammography, sonography, and physical examination. Multiple studies have shown breast MRI to be superior to conventional techniques in determining the size of the primary tumor as well as in identifying additional sites of otherwise occult malignancy. Delineation of the extent of disease is critical because staging will determine treatment choices and patient outcome. MRI in women with newly diagnosed breast cancer has been shown to influence surgical management. Preoperative MRI is most useful in women with large tumors (stage T2 or T3), those with invasive lobular carcinoma, and those with mammographically dense breasts [1]. The MRI study may detect a more extensive primary tumor than was previously suspected, such as the presence of an intraductal component around an invasive cancer. These additional findings require either a wider local excision or a change from breast conservation surgery to mastectomy. Fischer et al. [2] performed a retrospective analysis and concluded that preoperative breast MRI reduces the incidence of local recurrence. It is reasonable to assume that more accurate local staging should result in improved local control. However, randomized studies are needed to prove that preoperative MRI leads to a reduction of local recurrence. Note that surgical management should be planned only after tissue sampling has been obtained and should not be based solely on the MRI findings.

Breast MRI has a high sensitivity for the detection of occult multifocal, multicentric, or contralateral tumors. Multifocal disease is defined as tumor contained in one quadrant of the breast, and multicentric disease is defined as tumor in separate quadrants. Multiple studies have concluded that breast MRI is the most accurate imaging technique for local breast cancer staging in a woman with a recent diagnosis of breast cancer. In the ipsilateral breast, MRI may identify additional sites of otherwise occult malignancy in 15–27% of patients. Options A and B are not the best responses. Breast MRI will also identify unsuspected synchronous cancer in the contralateral breast in up to 3–10% of these women. In the American College of Radiology Imaging Network (ACRIN 6667) MRI Evaluation of the Contralateral Breast in Women Recently Diagnosed with Breast Cancer [3], contralateral cancer was identified in 3.1% of these women. Option C is not the best response. However, breast MRI has a limited sensitivity, 63–83%, for the detection of metastatic lymph nodes. Furthermore, MRI cannot detect micrometastasis to the lymph nodes. Several studies have concluded that MRI cannot take the place of axillary lymph node dissection or predict which patient will need sentinel versus a full axillary node dissection. **Option D is the best response.**

Note that no prospective study has shown that preoperative breast MRI has any significant impact on patient out-

come. Concern exists that the additional multifocal, multicentric, or contralateral disease detected on MRI may lead to overtreatment. This overtreatment includes unnecessary mastectomy and modified surgical treatment. Therefore, the findings detected on breast MRI and conventional imaging should be carefully discussed by a multidisciplinary team including the radiologist, the pathologist, the surgeon, the medical oncologist, and the radiation oncologist.

Solution to Question 2

Extensive multicentric disease may be a contraindication to breast conservation if a good cosmetic result cannot be obtained. If a woman is large-breasted, additional lumpectomies rather than a mastectomy are sometimes performed in an attempt to preserve the breast. Option A is not the best response. Extension of the primary tumor or satellite lesions to the areola or chest wall (serratus anterior, intercostal muscle, and ribs) is a contraindication to breast conservation surgery because negative margins cannot be obtained by the surgeon. These patients are treated with neoadjuvant chemotherapy. However, tumor extension to the pectoralis muscle is not a contraindication to breast conservation because a partial radical mastectomy can be performed. Morris et al. [4] noted that loss of the fat plane between a mass and the pectoralis muscle does not indicate pectoralis muscle invasion. Rather, enhancement of the pectoralis muscle must be present to suggest invasion. Options C and D are not the best response. Occasionally, a woman may present with a primary breast carcinoma with known involvement of the axillary lymph nodes. The involvement of the lymph nodes indicates that a sentinel lymph node dissection is not indicated. Rather, a full axillary lymph node dissection is performed. Some of these women may be candidates for neoadjuvant chemotherapy. However, nodal involvement does not preclude breast conservation therapy. **Option B is the best response.**

Solution to Question 3

Occasionally, a mammographic finding may be inconclusive even when additional problem-solving views and sonograms have been obtained. After the completion of a thorough workup, the addition of breast MRI may be helpful. The MRI study may be used to determine whether a finding seen on mammography is real. Moreover, its location can be ascertained. If a lesion seen on mammography or sonography is deemed suspicious enough to warrant biopsy, negative MRI findings should not alter this course of action. Therefore, if a lesion is deemed indeterminate, requiring biopsy under mammographic or sonographic guidance, this biopsy should be performed. MRI evaluation should not alter plans for biopsy [5].

For several abnormalities seen on mammography, MRI is requested as a problem-solving tool. These scenarios include evaluation of a focal asymmetry, whether it represents normal breast parenchyma or a lesion (invasive lobular carcinoma); evaluation of architectural distortion, whether it is present or not; evaluation of a proteinaceous cyst; evaluation and localization of a lesion seen on one view only; and differentiation between a scar and a recurrent cancer. If a change or a developing scar is seen in the lumpectomy site on the mammogram, a biopsy would be indicated regardless of the MRI findings. Options B, C, D, and E are not the best responses.

The determination of whether a cluster of microcalcifications is indeterminate or suspicious requiring biopsy should be made solely on the mammographic features of the microcalcifications. A negative MRI does not preclude the need to biopsy indeterminate or suspicious calcifications identified on mammography. However, once ductal carcinoma in situ (DCIS) is diagnosed, breast MRI can be useful in showing its full extent and in determining the possible presence of underlying invasive carcinoma [6]. **Option A is the best response.**

Solution to Question 4

Breast MRI allows the detection of extensive multicentric disease that is not seen on mammography or sonography. In this setting, the patient's local disease may be best treated with mastectomy. Option A is not the best response. If only multifocal disease is identified and the tumors are within 5 cm of each other, breast conservation can be attempted by performing a wider local excision than was originally planned [7]. Option C is not the best response. MRI may identify contraindications to surgery, such as a tumor that is locally advanced or invasion of the chest wall or areola. These patients are not initially surgical candidates. They undergo treatment with neoadjuvant chemotherapy in an attempt to shrink the tumor and possibly allow breast conservation surgery. Option D is not the best response. The sensitivity of MRI for metastatic lymph nodes is poor. MRI has been unable to predict which patient will need sentinel versus a full axillary node dissection [8]. **Option B is the best response.**

Solution to Question 5

MRI has been shown to be more sensitive than mammography for screening women who have an increased lifetime risk for breast cancer, in particular those with *BRCA1* and *BRCA2* mutations. Multiple studies have noted that MRI shows sensitivities ranging from 79% to 98% [9]. As a result, MRI is being increasingly used as a surveillance tool in this subset of high-risk women. In March 2007, the American Cancer Society (ACS) published new guidelines in the ACS journal, *Cancer: A Cancer Journal for Clinicians* [10]. The ACS recommends that certain women at very high risk of developing breast cancer should undergo yearly breast MRI examinations along with their yearly mammogram. The two examinations together may help detect breast car-

cinoma earlier in this subset of women, making it easier to treat when the chance of survival is greatest.

The new guidelines recommend MRI screening in addition to mammograms for women who meet at least one of the following conditions: they have a *BRCA1* or *BRCA2* mutation; they have a first-degree relative (parent, sibling, child) with a *BRCA1* or *BRCA2* mutation, even if they have yet to be tested themselves; their lifetime risk of breast cancer has been scored at 20–25% or greater, based on one of several accepted risk assessment tools that look at family history and other factors; they had irradiation to the chest between the ages of 10 and 30 years; and they have Li-Fraumeni syndrome, Cowden syndrome, or Bannayan-Riley-Ruvalcaba syndrome, or may have one of these syndromes based on a history in a first-degree relative. Options A, B, D, and E are not the best responses.

The guidelines state that there still is not enough evidence to recommend for or against MRI screening in women who have a higher-than-average risk of breast cancer. These include women who have a 15–20% lifetime risk of breast cancer, based on one of several accepted risk assessment tools that look at family history and other factors; have lobular carcinoma in situ or atypical lobular hyperplasia; have atypical ductal hyperplasia; have heterogeneously or extremely dense breasts on mammography; and have already had breast cancer, including DCIS. The ACS concludes that screening MRI examinations are not recommended for women with a lifetime risk of breast cancer of less than 15%. **Option C is the best response.**

Solution to Question 6

Women with isolated metastatic adenocarcinoma involving axillary lymph nodes are a well-recognized group of patients having carcinoma of unknown primary (CUP) cause. CUP represents fewer than 1% of all cases of breast carcinoma and tends to have a favorable prognosis. This group of patients is generally treated on the assumption that they have occult breast cancer. Studies have concluded that MRI identifies the primary breast cancer in 70% (range, 62–86%) of these women [11, 12]. These cancers are usually smaller than 2 cm. Breast MRI can detect these occult cancers irrespective of breast density [11]. Options A and B are not the best responses. MRI offers the potential not only for detection of cancer in the breast but also for staging the cancer. MRI can determine whether these patients are candidates for breast conservation therapy. Option D is not the best response.

Treatment is more complex in women with negative MRI of the breast. Management in these patients has traditionally been with a modified radical mastectomy, although tumor is identified in only two thirds of mastectomy specimens. **Option C is the best response.** However, the patient survival rate is not improved with a mastectomy, and several studies have concluded that further management with mastectomy in women with negative breast MRI is not mandatory [13]. Rather, these women may be treated with radiation therapy alone or may be observed and receive no local therapy at all. The management of these women is discussed by a multidisciplinary team of physicians and determined on a case-by-case basis.

Solution to Question 7

The drive to conserve breast tissue incorporates presurgical neoadjuvant chemotherapy, in which an attempt is made to shrink locally advanced tumors before surgery. The timing of surgical intervention can be altered on the basis of the response to chemotherapy; therefore, precise metrics for clinical response are critical. In women undergoing neoadjuvant chemotherapy, MRI can monitor response to therapy during treatment as well as identify residual tumor at the end of the course of chemotherapy. A metallic clip is deployed in the tumor under sonographic guidance before the start of chemotherapy. This metallic clip identifies the tumor bed when a complete response is achieved. Several studies have shown MRI to be superior to conventional imaging and clinical breast assessment for evaluating the early response to treatment and measuring residual disease after neoadjuvant chemotherapy. Option C is not the best response. The American College of Radiology Imaging Network has sponsored a multiinstitutional prospective clinical trial (ACRIN 6657) to assess the predictive role of MRI in measuring therapeutic response, including changes in tumor volume and vascularity.

The ability to assess a response to chemotherapy early in the course of treatment will have a substantial impact on clinical decisions. A costly and ineffective chemotherapy regimen may be changed. This will prevent further exposing of the patient to the toxicity of an ineffective chemotherapy and prevent an unnecessary delay in the patient's surgery. It would be ideal to perform MRI after the first cycle of chemotherapy has been completed. Several studies have shown that MRI can detect a response to treatment after the second chemotherapy cycle [14]. Option A is not the best response. MRI findings suggestive of a response to treatment include a decrease in tumor size and a decrease in tumor enhancement. Studies have also suggested that decreased perfusion to the breast may be an early sign of response. This effect is seen as a decreased rate of uptake of contrast agent in conjunction with absence of washout of contrast material. Overall, the decreased perfusion leads to a reduction in the peak contrast enhancement and a flattening of the enhancement curve. Option E is not the best response.

After neoadjuvant chemotherapy, MRI can be used to depict residual disease. Residual MRI tumor volume predicts recurrence-free survival rates. Findings seen on MRI have been shown to correlate significantly better with pathologic response than those found at conventional imaging or clinical examination [15]. Most studies conclude that MRI can overestimate residual disease. They have shown that changes seen

in response to chemotherapy may also show enhancement. However, some studies have suggested that certain chemotherapy agents may actually decrease the sensitivity of MRI and lead to an underestimation of residual disease [16]. Option B is not the best response. Moreover, MRI may also underestimate residual disease in women with invasive lobular carcinoma. Therefore, MRI cannot definitively exclude the presence of residual disease at the end of the course of chemotherapy. **Option D is the best response.**

Solution to Question 8

MRI has been found to be highly sensitive in the preoperative assessment of breast carcinoma and in the evaluation of extent of disease. MRI can detect intraductal carcinoma that is mammographically occult [17]. Tumor size as seen on MRI has been shown to correlate best with histologic tumor size, especially in women with large tumors. Most published studies have concluded that breast MRI is the most accurate imaging technique for staging of local breast cancer. Fischer et al. [2] performed a retrospective analysis to determine whether preoperative breast MRI reduces the incidence of local recurrence, and they concluded that it does. However, the two groups of patients were not randomized. Those patients who did not undergo preoperative MRI had larger tumors and tumors with higher histologic grades. Randomized studies comparing the outcome in patients with and those without preoperative MRI have not been performed. These randomized studies may allow us to draw conclusions as to the reduction of local recurrence. Options A, B, and C are not the best responses.

In the postoperative setting, MRI is also highly sensitive for distinguishing a developing scar from recurrent cancer and for detecting residual disease after breast conservation therapy. MRI is helpful in detecting local recurrence after breast conservation therapy. Mammography, sonography, and clinical breast examination may be limited by the changes caused by lumpectomy and radiation therapy. The sensitivity of mammography is limited by the architectural distortion caused by postsurgical changes. The sensitivity of sonography in these cases is also low because scar tissue often appears as an irregular area with posterior acoustic shadowing that is possibly hiding an underlying malignancy. A repeat excisional biopsy to exclude a recurrence may exacerbate this dilemma because it would likely lead to more scarring. The presence of a nonenhancing scar on MRI has a high negative predictive value for recurrent cancer. However, the reverse is not true because normal enhancement may be seen in the lumpectomy site for up to 18 months after the completion of radiation treatment [18]. **Option E is the best response.** Further, Morakkabati et al. [19] prospectively investigated the degree and prevalence of irradiation-induced changes on MRI in patients who had radiotherapy at that time or soon after. They concluded that radiotherapy led to parenchymal edema and an increase in enhancement rates in the irradiated breast during and up to 3 months after radiotherapy, but that the changes are much less severe than reported. After 3 months, irradiation-induced effects did not impair the diagnostic accuracy of MRI.

Breast MRI is quite helpful in determining the extent of residual tumor after results from initial lumpectomy yield positive surgical margins. MRI can not only determine whether a patient is a candidate for breast conservation, it can also guide surgical planning. Normal granulation tissue may enhance, limiting the sensitivity and specificity of breast MRI in the postoperative breast. Frei et al. [20] have concluded that breast MRI is most sensitive for the detection of residual disease 35–42 days after lumpectomy. However, most surgeons and patients are reluctant to wait this long for reexcision. We advocate performing breast MRI in the immediate postoperative period—within the first week—to assess for residual disease. During this time, the surgical cavity is usually distended and is seen as a low-signal fluid collection on T1-weighted images. The seroma cavity may serve as contrast to any enhancing tumor that may be present. A distended surgical cavity may facilitate the assessment of asymmetric enhancement in the tissue adjacent to the cavity. The asymmetric enhancement in the tissue adjacent to the surgical cavity may be readily detected and may be suggestive of residual disease. Option D is not the best response.

Solution to Question 9

Approximately 260,000 American women underwent breast augmentation in 2004, and an additional 60,000 did so after surgery for breast cancer. Because of health concerns, the U.S. Food and Drug Administration (FDA) in recent years has limited the use of silicone gel implants. Silicone gel implants are now placed only in women with mastectomies and in those enrolled in clinical trials; all others receive implants filled with a saline solution. In November 2006, 14 years after silicone gel implants were removed from the market because of questions of safety, the FDA approved their marketing and sale by two manufacturers, Allergan and Mentor. The FDA states that these implants are approved "for breast reconstruction in women of all ages and breast augmentation in women ages 22 and older."

After a silicone prosthesis has been implanted in the breast, the body forms a fibrous capsule of scar tissue around the implant. Implant rupture occurs in approximately 50% of implants that are 12 years old. Most cases of implant rupture are intracapsular; leakage of silicone or saline from the implant remains contained in the fibrous capsule. Intracapsular rupture is also called a "silent rupture" because it is not detected on mammography or clinical breast examination.

Several studies have found MRI to be superior to mammography and sonography for the detection of intracapsular silicone implant rupture. Goodman et al. [21] performed a meta-analysis of these three imaging techniques and con-

cluded that the mean sensitivity was 38% for mammography, 59% for sonography, and 78% for MRI. The ability of sonography to detect intracapsular rupture is limited because normal folds can occur in an intact implant and mimic the sonographic signs of implant rupture. Rarely, on sonography, a stepladder sign may be detected in which multiple discontinuous parallel linear echoes are identified in the lumen. This is the most reliable sonographic finding of intracapsular rupture, analogous to the linguine sign on MRI. MRI signs of a complete intracapsular rupture include the linguine sign, a series of dark curvilinear lines in the implant. These lines represent the collapsed silicone shell floating in the center of the implant material. The keyhole sign, a loop of silicone shell prolapsed into the implant lumen producing a keyhole appearance, suggests partial collapse of the implant shell. Options C and D are not the best responses.

With extracapsular implant rupture, the silicone is extruded outside the fibrous capsule, often extending into the axilla. Silicone can sometimes be seen in axillary lymph nodes. The contour deformity of the ruptured implant and the presence of free silicone granulomas can be readily identified on mammography, sonography, and MRI. Women with these implants may be symptomatic and present with implant flattening, lumps, and silicone extrusion. Option E is not the best response.

MRI has no role in the evaluation of saline implants because rupture of saline implants is a clinical diagnosis. When a saline implant ruptures, the saline is reabsorbed by the body, with an obvious change in the size and shape of the breast. Option B is not the best response.

Mammography is of limited value in women who undergo breast augmentation because it is difficult to separate the breast parenchyma from the implant. This problem is exacerbated if the implant has been placed in a prepectoral or retroglandular location. Breast MRI, however, allows the detection of breast cancer around or behind the implant. Therefore, MRI should be performed to diagnose breast cancer in this subset of women. At this time, no guidelines exist for determining among the women with implants who should undergo MRI to detect occult breast cancer. **Option A is the best response.**

Solution to Question 10

Invasive lobular carcinoma is the second most common type of breast carcinoma, after infiltrating ductal carcinoma (IDC). Invasive lobular carcinoma, which accounts for 5–15% of all breast cancers, has unique histologic features, including a linear file arrangement of cells and a diffuse infiltrative growth pattern. The sensitivity of physical examination for invasive lobular carcinoma is 65–98%,with more than 50% of patients presenting with palpable abnormalities. In the literature, the sensitivity of mammography for invasive lobular carcinoma is 81–92%. The reported sensitivity of sonography for invasive lobular carcinoma is 68–98%, with an overall sensitivity of 83%. Contrast-enhanced MRI has an overall sensitivity of 93.3% [22]. Option A is not the best response.

Invasive lobular carcinoma may have a variable appearance on mammography and MRI. It appears on mammography as a poorly defined opacity, parenchymal asymmetry, spiculated mass, or architectural distortion. On MRI, most invasive lobular carcinomas are described as mass lesions with malignant features (irregular or spiculated shape) [22]. The more diffuse growing tumors are characterized as nonmasslike enhancement and are more difficult to recognize. Overall, the appearance of most invasive lobular carcinomas on MRI and mammography is similar. Option B is not the best response.

Mammography and sonography tend to underestimate lesion size and extent. This has been attributed to the tumor growth pattern. In a study by Krecke and Gisvold [23], the false-negative rate for the diagnosis of invasive lobular carcinoma on mammography was 46%. Sonography also tends to underestimate tumor size. Rodenko et al. [24] found that the extent of disease pathologically correlated with that predicted by MRI in 85% of patients, compared with a 32% correlation for mammography. The importance of adequate estimation of tumor size in patients with invasive lobular carcinoma is stressed by the observation that margin status after breast conservation therapy is more often compromised in invasive lobular carcinoma than in IDC. As a consequence, reexcision and conversion to mastectomy are more common for invasive lobular carcinoma than for IDC [25]. Option D is not the best response.

Invasive lobular carcinoma also tends to be more often multifocal or multicentric (14–31%) than IDC [26]. In many cases, the additional foci of disease are not seen on mammography and sonography. Rodenko et al. [24] concluded that MRI defined the extent of disease, including the presence of multifocal and multicentric disease, better than mammography. Furthermore, invasive lobular carcinoma has a high propensity for bilateral disease. An additional 7% of patients have contralateral cancer that is detected on MRI only. The detection of this additional disease on preoperative MRI led to changes in surgical management in 28% of the cases, of which 88% were judged necessary on the basis of pathology [22]. **Option C is the best response.**

References

1. Bartella L, Morris EA. Advances in breast imaging: magnetic resonance imaging. *Curr Oncol Rep* 2006; 8:7–13
2. Fischer U, Zachariae O, Baum F, von Heyden D, Funke M, Liersch T. The influence of preoperative MRI of the breasts on recurrence rate in patients with breast cancer. *Eur Radiol* 2004; 14:1725–1731
3. Lehman CD, Gatsonis C, Kuhl CK, et al. MRI evaluation of the contralateral breast in women with recently diagnosed breast cancer. *N Engl J Med* 2007; 356:1295–1303
4. Morris EA, Schwartz LH, Drotman MB, et al. Evaluation of pectoralis major muscle in patients with posterior breast tumors on breast MR images: early

experience. *Radiology* 2000; 214:67–72
5. Lee CH, Smith RC, Levine JA, Troiano RN, Tocino I. Clinical usefulness of MR imaging of the breast in the evaluation of the problematic mammogram. *AJR* 1999; 173:1323–1329
6. Kuhl CK, Schrading S, Bieling HB, et al. MRI for diagnosis of pure ductal carcinoma in situ: a prospective observational study. *Lancet* 2007; 370:485–492
7. Jatoi I, Proschan MA. Randomized trials of breast-conserving therapy versus mastectomy for primary breast cancer: a pooled analysis of updated results. *Am J Clin Oncol* 2005; 28:289–294
8. Luciani A, Itti E, Rahmouni A, Meignan M, Clement O. Lymph node imaging: basic principles. *Eur J Radiol* 2006; 58:338–344
9. Kriege M, Brekelmans CT, Boetes C, et al. Efficacy of MRI and mammography for breast-cancer screening in women with a familial or genetic predisposition. *N Engl J Med* 2004; 351:427–437
10. Saslow D, Boetes C, Burke W, et al. American Cancer Society guidelines for breast screening with MRI as an adjunct to mammography. *CA Cancer J Clin* 2007; 57:75–89
11. Buchanan CL, Morris EA, Dorn PL, Borgen PI, Van Zee KJ. Utility of breast magnetic resonance imaging in patients with occult primary breast cancer. *Ann Surg Oncol* 2005; 12:1045–1053
12. Orel SG, Weinstein SP, Schnall MD, et al. Breast MR imaging in patients with axillary node metastases and unknown primary malignancy. *Radiology* 1999; 212:543–549
13. Olson JA Jr, Morris EA, Van Zee KJ, Linehan DC, Borgen PI. Magnetic resonance imaging facilitates breast conservation for occult breast cancer. *Ann Surg Oncol* 2000; 7:411–415
14. El Khoury C, Servois V, Thibault F, et al. MR quantification of the washout changes in breast tumors under preoperative chemotherapy: feasibility and preliminary results. *AJR* 2005; 184:1499–1504
15. Rieber A, Brambs HJ, Gabelmann A, Heilmann V, Kreienberg R, Kuhn T. Breast MRI for monitoring response of primary breast cancer to neo-adjuvant chemotherapy. *Eur Radiol* 2002; 12:1711–1719
16. Denis F, Desbiez-Bourcier AV, Chapiron C, Arbion F, Body G, Brunereau L. Contrast enhanced magnetic resonance imaging underestimates residual disease after neoadjuvant docetaxel based chemotherapy for breast cancer. *Eur J Surg Oncol* 2004; 30:1069–1076
17. Van Goethem M, Schelfout K, Kersschot E, et al. MR mammography is useful in the preoperative locoregional staging of breast carcinomas with extensive intraductal component. *Eur J Radiol* 2007; 62:273–282
18. Heywang-Kobrunner SH, Schlegel A, Beck R, et al. Contrast-enhanced MRI of the breast after limited surgery and radiation therapy. *J Comput Assist Tomogr* 1993; 17:891–900
19. Morakkabati N, Leutner CC, Schmiedel A, Schild HH, Kuhl CK. Breast MR imaging during or soon after radiation therapy. *Radiology* 2003; 229:893–901
20. Frei KA, Kinkel K, Bonel HM, Lu T, Esserman LJ, Hylton NM. MR imaging of the patients with positive margins after lumpectomy: influence of the time interval between lumpectomy and MR imaging. *AJR* 2000; 175:1577–1584
21. Goodman CM, Cohen V, Thornby J, Netscher D. The life span of silicone gel breast implants and a comparison of mammography, ultrasonography, and magnetic resonance imaging in detecting implant rupture: a meta-analysis. *Ann Plast Surg* 1998; 41:577–585
22. Mann RM, Hoogeveen YL, Blickman JG, et al. MRI compared to conventional diagnostic work-up in the detection and evaluation of invasive lobular carcinoma of the breast: a review of existing literature. *Breast Cancer Res Treat* 2008; 107:1–14
23. Krecke KN, Gisvold JJ. Invasive lobular carcinoma of the breast: mammographic findings and extent of disease at diagnosis in 184 patients. *AJR* 1993; 161:957–960
24. Rodenko GN, Harms SE, Pruneda JM, et al. MR imaging in the management before surgery of lobular carcinoma of the breast: correlation with pathology. *AJR* 1996; 167:1415–1419
25. Dillon MF, Hill AD, Fleming FJ, et al. Identifying patients at risk of compromised margins following breast conservation for lobular carcinoma. *Am J Surg* 2006; 191:201–205
26. Lesser ML, Rosen PP, Kinne DW. Multicentricity and bilaterality in invasive breast carcinomas. *Surgery* 1989; 91:234–240

Radiological Reasoning: Algorithmic Workup of Abnormal Vaginal Bleeding with Endovaginal Sonography and Sonohysterography

Ann A. Shi[1,2] and Susanna I. Lee[1]

OBJECTIVE

The workup of endometrial abnormalities can be a confusing task for radiologists because one must take into account the patient's clinical history, imaging findings, and a wide array of diagnostic options. We present two cases, one of a premenopausal woman presenting with vaginal bleeding and another of a postmenopausal woman taking tamoxifen who has abnormal findings on endovaginal sonography. The evaluations of these patients serve to illustrate the diagnostic algorithm for identification of endometrial pathology.

CONCLUSION

Imaging plays a central role in the algorithm for detection of endometrial disorders in women with abnormal vaginal bleeding. Endovaginal sonography is used to identify mural abnormalities such as fibroids and adenomyosis and to screen for thickened endometria that require nonfocal biopsy for the diagnosis of cancer or hyperplasia. Sonohysterography serves as a triage tool to detect focal abnormalities of the endometrial cavity, such as endometrial polyps or subendometrial fibroids, thereby identifying those women who require more invasive workup with hysteroscopy.

Case History, Patient 1

A 32-year-old nulligravida woman with no significant medical history presents complaining of significant intermenstrual bleeding. Her pelvic examination is normal. Her uterus is small, mobile, and nontender. No adnexal masses or tenderness is noted. Her β-HCG is negative. A trial of hormonal therapy has not been successful. Pelvic sonography is performed.

Sonography

On endovaginal sonography (Fig. 1A), a 15-mm homogeneously echogenic endometrial echo complex is noted, which is within normal limits. A "hyperechoic line sign" [1], a line circumscribing the central endometrial complex, is seen, suggesting a focal intracavitary abnormality such as a polyp. Sonohysterography is recommended.

Expert Discussion (Dr. Lee)

In premenopausal women with bleeding, benign causes—for example, endometrial polyps and fibroids—constitute most of the abnormalities detected on imaging. Endovaginal sonography is a good first step to screen for mural as well as endometrial abnormalities. However, the diagnostic performance of endovaginal sonography for detecting endometrial pathology in premenopausal women is moderate, with sensitivity and specificity of 67% and 75%, respectively, using an endometrial thickness cutoff of > 16 mm [2].

If endovaginal sonography indicates endometrial abnormality, nonfocal endometrial biopsy should be performed to exclude cancer or hyperplasia—that is, diffuse endometrial pathology. Even if cancer is an unlikely possibility, it should not be missed because it is the one cause of abnormal vaginal bleeding that is life-threatening. A nonfocal biopsy is a relatively noninvasive, inexpensive office procedure to evaluate for endometrial cancer. Once biopsy is negative for cancer or hyperplasia (a premalignant lesion), workup should continue to evaluate for the focal benign cause of bleeding.

This patient shows a homogeneous endometrial echo complex that has a thickness that is within normal limits. Thus, the vaginal bleeding is unlikely secondary to a diffuse endometrial process, such as endometrial carcinoma, and a nonfocal biopsy is not indicated. The next step is to evaluate for focal causes for bleeding, which are best detected by sonohysterography.

Sonohysterography

The endometrium measures 1 mm anteriorly and 1 mm posteriorly. In the endometrial canal is a 2.5 × 1.7 cm homogeneously hyperechoic lesion, with attachment at the 6-o'clock position on coronal images, and showing a central stalk on color Doppler imaging (Fig. 1B).

Expert Discussion (Dr. Lee)

The differential diagnosis of focal endometrial abnormality seen on sonohysterography includes polyp, subendometrial fibroid, focal cancer, and hyperplasia. Although cancer

Keywords: algorithm, endometrium, premenopause, postmenopause, tamoxifen

DOI:10.2214/AJR.07.7067

Received December 27, 2007; accepted after revision March 5, 2008.

[1]Department of Radiology, Massachusetts General Hospital, Boston, MA.

[2]Present address: Department of Radiology, Montefiore Medical Center, 111 E 210th St., Bronx, NY 10467. Address correspondence to A. A. Shi (ashi@montefiore.org).

AJR 2008;191:SXX–SXX 0361–803X/08/1916–SXX

and hyperplasia are a consideration, they would more typically show a broad base of attachment and appear diffuse.

Endometrial polyps are localized hyperplastic overgrowths of endometrial glands and stroma around a vascular core that form a sessile or pedunculated projection from the surface of the endometrium. Single or multiple polyps can occur ranging from a few millimeters to several centimeters in size. On sonohysterography, polyps appear as echogenic, smooth, intracavitary masses outlined by fluid [3, 4]. Color Doppler images may show a single feeding artery at the base of attachment, as seen in this patient, a finding frequently seen with polyps [5].

The sonographic appearance of polyps can be variable. Cystic spaces corresponding to dilated glands filled with proteinaceous fluid may also be seen. The polyp may show a narrow stalk but can occasionally appear broad-based or sessile. The point of attachment does not disrupt the endometrial lining. At times polyps show heterogeneous echotexture, indicating hemorrhage, infarction, or inflammation [6]. Foci of hyperplasia or malignant degeneration cannot be excluded with imaging. Thus, even though most polyps are benign, those that cause bleeding are resected for histologic evaluation to exclude malignancy.

Another cause of focal endometrial abnormality on sonohysterography is subendometrial fibroids. Subendometrial fibroids are typically hypoechoic, well-defined solid masses, with either a narrow or a broad base of attachment. Most important, they show an overlying layer of echogenic endometrium. They often distort the interface between the endometrium and myometrium and show acoustic attenuation. Subendometrial fibroids are often larger than polyps and may show multiple feeding vessels [7]. The key to differentiating the two entities is to ascertain the location of the endometrial lining with regard to the lesion. In this patient, a fibroid is not likely because the endometrium subtends the focal lesion.

Endometrial hyperplasia is caused by unopposed estrogen stimulation. Risk factors include endogenous or exogenous exposure to estrogen, use of tamoxifen, nulliparity, obesity, hypertension, and diabetes. On sonohysterography, endometrial hyperplasia usually appears as a diffuse thickening of the endometrial echo complex. Although hyperplasia typically presents as a diffuse endometrial abnormality, focality is occasionally seen.

Endometrial cancer has the same risk factors and overlapping imaging appearance as hyperplasia. The most common appearance is nonspecific thickening. On sonohysterography, the diagnosis should be suspected when a single layer is thicker than 8 mm, irregular, broad-based, poorly marginated, or when the endometrial–myometrial interface is disrupted [5]. On occasion, early cases of endometrial cancer can be polypoid.

In summary, the imaging features of the endometrial abnormality in this premenopausal patient are most in keeping with an endometrial polyp. However, fibroids, focal endometrial hyperplasia, or carcinoma can mimic a sessile polyp, and foci of atypical hyperplasia are sometimes found in polyps. The next step in the workup of this patient is histologic resection of the focal endometrial lesion under hysteroscopic guidance.

Hysteroscopy

Visualization of the endometrial cavity reveals it to be completely normal in size, shape, and position. A 2.5-cm

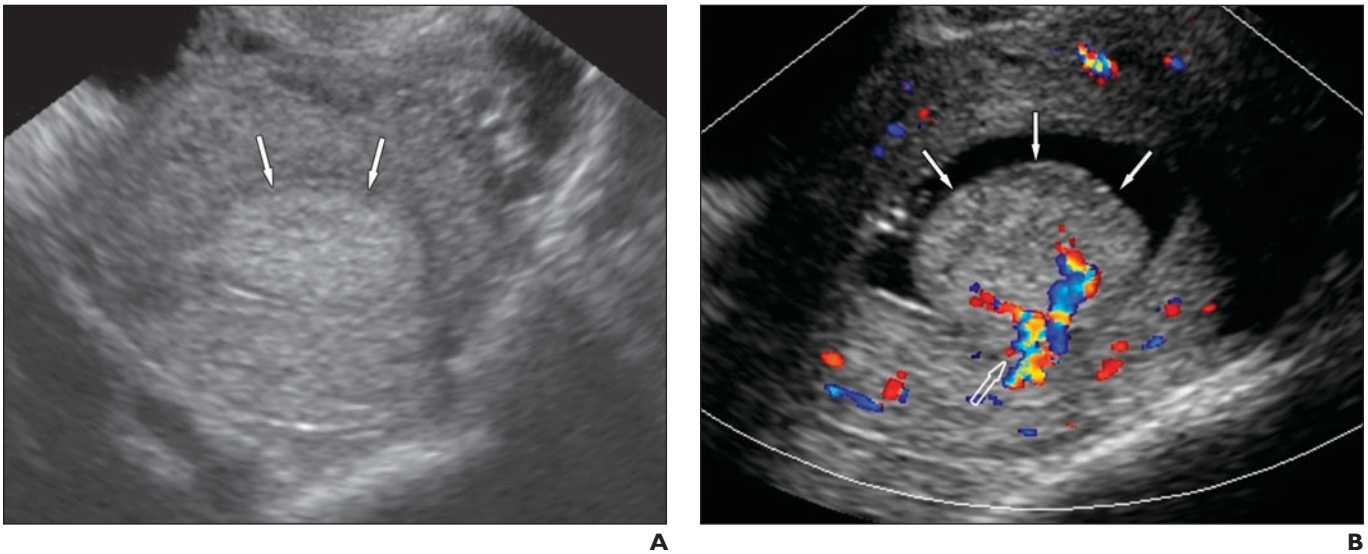

Fig. 1—32-year-old premenopausal woman with abnormal vaginal bleeding.
A, Coronal endovaginal sonogram shows endometrial echo complex measuring 15 mm, which is within normal limits. Note hyperechoic line (*arrows*) circumscribing thickened endometrium, suggesting focal endometrial abnormality.
B, Color Doppler sonohysterogram shows hyperechoic intracavitary lesion (*solid arrows*) and stalk of increased vascular flow (*open arrow*).

endometrial polyp is attached to a narrow stalk on the posterior wall of the uterus.

Pathology

Three fragments of tan and pink glistening polypoid soft tissue were obtained, measuring in aggregate 2.7 × 2.2 × 0.9 cm. They were negative for malignancy.

Case History, Patient 2

A 68-year-old woman with a history of stage T1b, N0 invasive ductal carcinoma of the right breast has been taking tamoxifen for 2 years. The patient is G5, P6, underwent menopause at age 50, and has undergone 12 years of progesterone-only hormone replacement therapy. She experienced an episode of pelvic pain but denies vaginal bleeding. Physical examination of the abdomen and pelvis is normal. She is referred for pelvic sonography.

Sonography

The endometrial echo complex shows apparent thickening (Fig. 2A) measuring 16 mm. Multiple cystic structures are noted in the endometrial echo complex that could be either subendometrial or endometrial. Differential considerations include an endometrial process, such as a polyp or hyperplasia, or a subendometrial process, such as cystic subendometrial atrophy. Because the subsequent nonfocal endometrial biopsy reveals only atrophy, sonohysterography is recommended to differentiate.

Expert Discussion (Dr. Lee)

The use of tamoxifen as an adjunctive treatment for breast cancer has resulted in an increased prevalence of endometrial polyps, hyperplasia, and carcinoma. This drug is an estrogen antagonist in the breast but has a weak estrogenic effect in the uterus [8, 9]. Because of the resulting

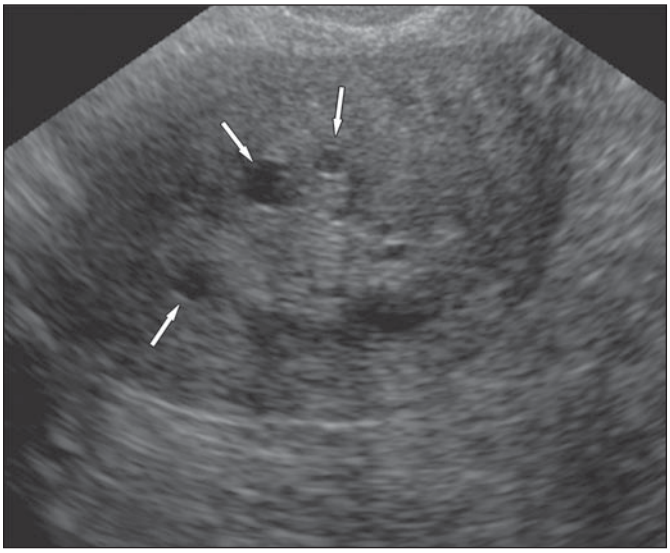

A

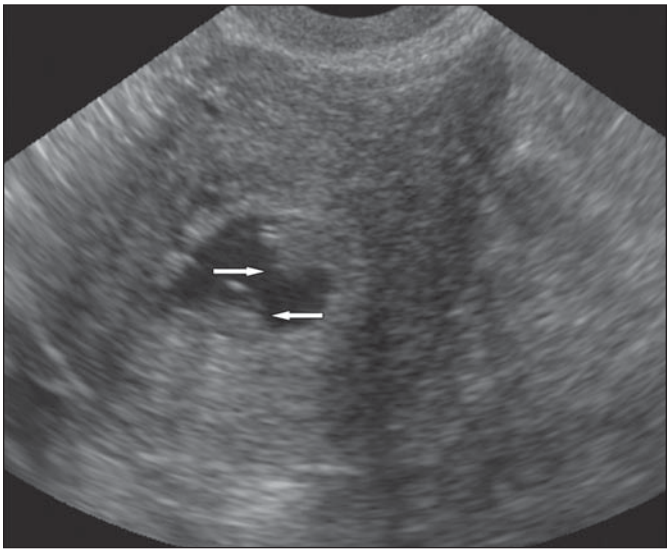

B

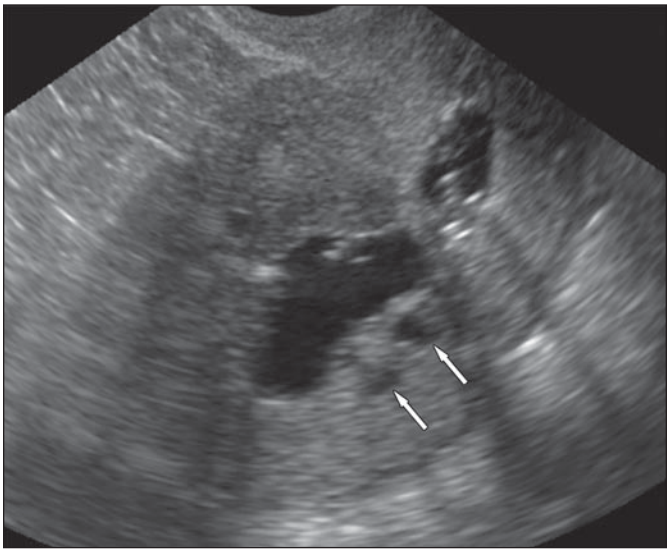

C

Fig. 2—68-year-old postmenopausal woman receiving tamoxifen.
A, Transvaginal sonography shows multiple cystic foci (*arrows*) that may be either subendometrial or endometrial. Endometrial echo complex appears thick, measuring 16 mm.
B, Sonohysterography shows two polypoid lesions (*arrows*) in endometrial canal.
C, Second sonohysterography image shows cystic changes (*arrows*) subtending echogenic endometrial lining, a finding commonly seen with tamoxifen use.

increased risk for endometrial malignancy, endometrial abnormalities detected on sonography should be worked up aggressively in this group of patients.

On screening endovaginal sonography, postmenopausal women taking tamoxifen show endometria that are frequently thicker than those of control subjects [9], and the thickness seems to correlate with duration of tamoxifen treatment [10]. Most women with thickened endometria are asymptomatic. Some investigators have proposed using 5–8 mm as a cutoff for diagnosing endometrial abnormalities on endovaginal sonography in asymptomatic postmenopausal women receiving tamoxifen [11–13].

The cystic changes seen in this patient may be associated with an endometrial polyp, subendometrial cystic atrophy related to tamoxifen, or adenomyosis. Thus, in patients who have had long-term exposure to tamoxifen, it is often difficult to delineate an endometrial from a subendometrial process on endovaginal sonography. Furthermore, abnormalities such as endometrial polyp or carcinoma coexist, limiting the use of endovaginal sonography in the diagnosis of specific abnormalities in this patient population [14].

Because in this patient endovaginal sonography indicates apparent thickening of the endometrium, the first step in management is a nonfocal endometrial biopsy to evaluate for cancer or hyperplasia. When this proves negative, the next step is to proceed with a workup for a focal abnormality. Sonohysterography has been shown to perform more accurately than endovaginal sonography in the detection of focal endometrial abnormalities [10, 14] and to obviate surgery in some cases [15].

Sonohysterography

An 8-mm polypoid lesion and a 6-mm polypoid lesion arising from the posterior endometrium (Fig. 2B) are noted. The cystic changes that appeared as apparent endometrial thickening on endovaginal sonography are shown on sonohysterography to be subendometrial and consistent with the patient's history of chronic tamoxifen exposure (Fig. 2C).

Expert Discussion (Dr. Lee)

Cystic spaces in the uterine myometrium are a frequent finding in patients receiving tamoxifen. Some investigators believe that the cystic spaces reside in the inner myometrium and are associated with an increased prevalence of adenomyosis or adenomyosis-like changes [16]. Others hypothesize that these changes are due to atrophy [17]. Regardless of the cause, the cystic changes may simulate endometrial thickening on endovaginal sonography. Sonohysterography distinguishes endometrial from subendometrial abnormalities. Thus, in women with chronic tamoxifen exposure and abnormalities on endovaginal sonography, sonohysterography can be used to triage those requiring hysteroscopic resection of focal endometrial abnormalities from those who have no endometrial abnormalities.

The differential diagnosis for polypoid lesions arising from the posterior wall is an endometrial polyp and, less likely, focal hyperplasia or cancer. As with the previous patient, because imaging cannot exclude endometrial malignancy, the next step is histologic evaluation.

Hysteroscopy

Two foci of posterior endometrial thickening are seen, consistent with polyps. Biopsy of the focal lesions as well as the nonthickened surrounding endometrium is performed.

Pathology

Biopsy of the focal lesions reveals marked glandular atypia consistent with a polyp or reparative change. Atrophy is noted in the biopsy of the surrounding nonthickened endometrium.

Commentary

Figure 3 presents an algorithm for evaluating abnormal vaginal bleeding in both pre- and postmenopausal women. The major diagnostic tools include endovaginal sonography, nonfocal endometrial biopsy, sonohysterography, and hysteroscopy.

Endometrial lesions are classified as nonfocal (cancer and hyperplasia) or focal (polyps and submucosal fibroids). Nonfocal abnormalities are considered malignant or premalignant, whereas most focal lesions are benign. Endometrial cancer is a relatively rare cause of abnormal bleeding, estimated to account for 10% of postmenopausal bleeding, and probably even an order of magnitude less of premenopausal abnormal bleeding [18]. However, cancer is the only cause of vaginal bleeding from an endometrial source that is potentially lethal; hence, the primary goal in the workup of abnormal bleeding is to exclude malignancy. Only after cancer has been deemed unlikely, either by lack of patient risk factors, normal endometrial thickness on endovaginal sonography, or negative nonfocal endometrial biopsy, should a focal, more likely benign cause be sought to explain the bleeding. The tools for identifying focal abnormalities are sonohysterography and hysteroscopy.

Sonohysterography and hysteroscopy show similar performance characteristics with regard to sensitivity (95–96%) and specificity (88–90%) for detecting and characterizing focal endometrial abnormalities [19, 20]. Hysteroscopy has the advantage of yielding a tissue diagnosis, with the drawback of greater patient discomfort, expense, and, rarely, the major complication of uterine perforation. Sonohysterography is less invasive, less expensive, well tolerated, and without major complications. In addition, sonohysterography provides a road map for hysteroscopic resection of intracavitary lesions and reduces the number of negative hysteroscopies. Nonetheless, it is an added step in the workup, and its role in the diagnostic algorithm of endometrial abnormality remains to be investigated [21, 22]. Among the subset of postmenopausal women taking tamoxifen, however, in whom endovaginal sonography results are often

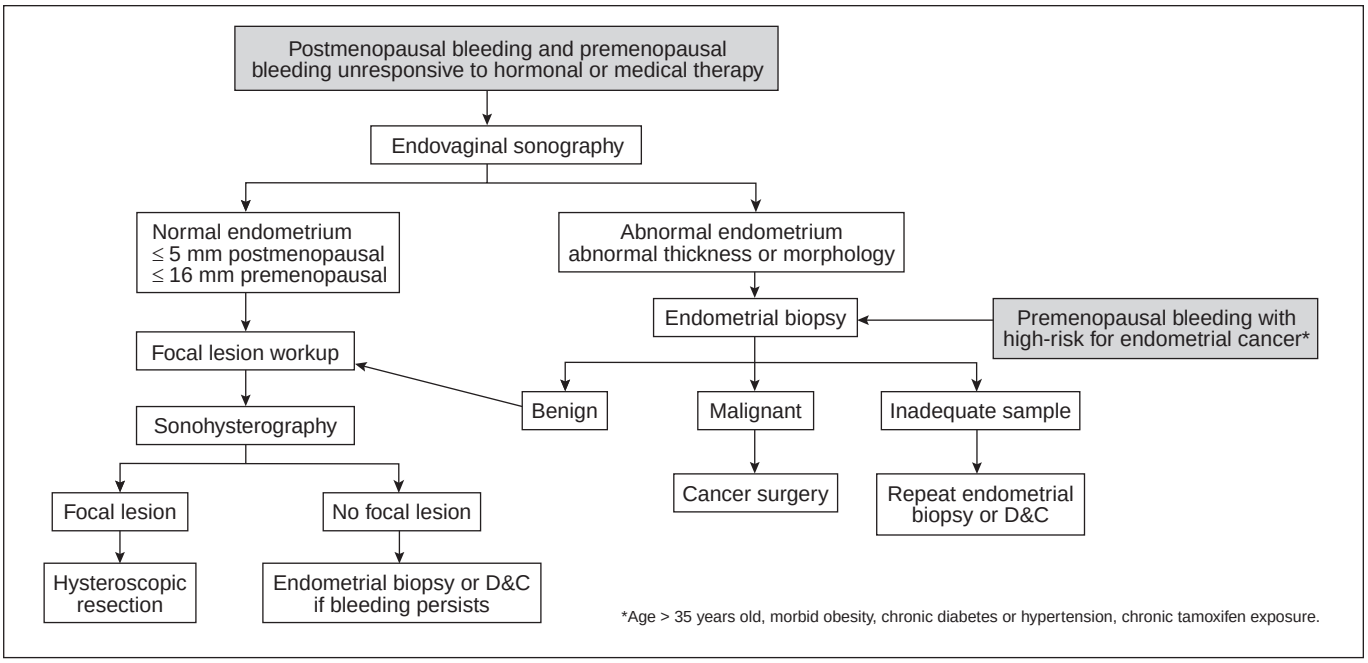

Fig. 3—Algorithm for evaluating women with abnormal vaginal bleeding. In asymptomatic postmenopausal women, endometrial thickness of > 6 mm (for patients not undergoing hormone replacement therapy) or > 8 mm (for those receiving hormone replacement therapy) is considered abnormal and should trigger a similar workup for endometrial abnormalities [24]. Threshold for workup of asymptomatic women taking tamoxifen is controversial, with endometrial thickness cutoffs of 5–8 mm having been proposed. D&C = dilatation and curettage.

nonspecific, sonohysterography is useful for distinguishing endometrial from subendometrial abnormalities and thereby guiding diagnostic workup [8].

In most premenopausal women, endometrial cancer is rare. The most common cause of bleeding is hormonal or mural lesions (e.g., fibroids or adenomyosis). Thus, the first step in managing a premenopausal woman who is not at high risk for endometrial cancer—high-risk factors are age > 35 years, morbid obesity, chronic hypertension, chronic diabetes, and chronic tamoxifen exposure—is a trial of hormonal therapy. Sonography is usually performed to evaluate for mural lesions. Endovaginal sonography is less useful for the detection of endometrial abnormalities because normal endometrial thickness varies widely in the premenopausal population. In general, a thickness of greater than 16 mm in a symptomatic patient is considered abnormal, but with suboptimal sensitivity (67%) and specificity (75%) [2]. If hormonal therapy fails, if woman is at high risk for endometrial cancer, or if endovaginal sonography shows an endometrial abnormality, endometrial biopsy is performed to evaluate for cancer or hyperplasia. If the nonfocal biopsy is negative for cancer, then workup proceeds with sonohysterography or hysteroscopy to evaluate for focal lesions.

In postmenopausal women, the most likely causes of abnormal bleeding are benign, such as fibroids, endometrial polyps, or atrophy. However, abnormal bleeding in postmenopausal women carries a much higher likelihood of harboring malignancy than in premenopausal women. Thus, in postmenopausal women, endovaginal sonography is a well-tolerated, inexpensive way to initially screen for endometrial cancer. With an endometrial thickness cutoff of > 5 mm considered abnormal, endovaginal sonography is the most sensitive technique for detecting endometrial cancer (96% sensitivity), better than nonfocal biopsy (87% sensitivity), sonohysterography (89% sensitivity), or hysteroscopy (86% sensitivity) [18, 23]. For symptomatic postmenopausal women, a thickness of < 5 mm indicates that bleeding is likely secondary to endometrial atrophy [24].

The algorithm for working up postmenopausal women undergoing hormone replacement therapy follows similar reasoning, using endovaginal sonography as the first-line screening technique for endometrial cancer. A thickness of 8 mm is considered the upper limit of normal if the patient is asymptomatic [25]. However, if the patient reports postmenopausal bleeding, a thickness cutoff of > 5 mm is used with a sensitivity for cancer similar to that in women who are not receiving hormone replacement therapy [26].

For women taking tamoxifen, endovaginal sonography is of limited usefulness in evaluating the endometrium because tamoxifen-induced subendometrial changes can mimic a thickened endometrial echo complex. Thus, what is considered normal endometrial thickness in an asymptomatic woman is controversial in this patient population. However, because of the higher risk of malignancy among these patients, abnormal vaginal bleeding requires further evaluation, starting with nonfocal biopsy to exclude malig-

nancy, regardless of endometrial thickness [27]. Sonohysterography plays an important role as an adjuvant to endovaginal sonography by delineating endometrial and subendometrial disorders and selecting patients requiring hysteroscopy.

The role of MRI in the workup of abnormal vaginal bleeding is less clear. MRI is indicated if bleeding is attributed to leiomyomas and myomectomy is contemplated, or if sonography is indeterminate in differentiating adenomyosis from leiomyomas [28]. MRI may also be appropriate in patients who cannot undergo endovaginal sonography or in those with an equivocal or abnormal endovaginal sonography finding who cannot undergo sonohysterography.

Conclusion

Histology constitutes the definitive diagnosis in all women with abnormal vaginal bleeding that is unresponsive to medical or hormonal therapy. However, imaging plays a key role in screening and diagnostic triage. Endovaginal sonography is used to identify mural abnormalities, such as fibroids and adenomyosis, and to screen for thickened endometria, which require nonfocal biopsy to detect cancer or hyperplasia. Sonohysterography is a powerful tool for evaluating the endometrial cavity for focal abnormalities such as endometrial polyps or submucosal fibroids. It thereby identifies those women who require more invasive workup with hysteroscopy and provides a roadmap for hysterscopic resection of intracavitary lesions.

References

1. Baldwin MT, Dudiak KM, Gorman B, Mark CA. Focal intracavitary masses recognized with the hyperechoic line sign at endovaginal US and characterized with hysterosonography. *RadioGraphics* 1999; 19:927–935
2. Smith P, Bakos O, Heimer G, Ulmsten U. Transvaginal ultrasound for identifying endometrial abnormality. *Acta Obstet Gynecol Scand* 1991; 70:591–594
3. Jorizzo JR, Chen MYM, Riccio GJ. Endometrial polyps: sonohysterographic evaluation. *AJR* 2001; 176:617–621
4. Dubinsky TJ, Parvey HR, Gormaz G, et al. Transvaginal hysterosonography in the evaluation of small endoluminal masses. *J Ultrasound Med* 1995; 14:1–6
5. Davis PC, O'Neill MJ, Yoder IC, Lee SI, Mueller PR. Sonohyterographic findings of endometrial and subendometrial conditions. *RadioGraphics* 2002; 22:803–816
6. Bradley LD, Falcone T, Magen AB. Radiographic imaging techniques for the diagnosis of abnormal uterine bleeding. *Obstet Gynecol Clin North Am* 2000; 27:245–276
7. Tamura-Sadamori R, Emoto M, Naganuma Y, Hachisuga T, Kawarabayashi T. The sonohysterographic difference in submucosal uterine fibroids and endometrial polyps treated by hysteroscopic surgery. *J Ultrasound Med* 2007; 26:941–946
8. Fong K, Causer P, Atri M, Lytwyn A, Kung R. Transvaginal US and hysterosonography in post-menopausal women with breast cancer receiving tamoxifen: correlation with hysteroscopy and pathologic study. *RadioGraphics* 2003; 23:137–155
9. Cohen I, Rosen DJ, Shapira J, et al. Endometrial changes with tamoxifen: comparison between tamoxifen-treated and nontreated asymptomatic, postmenopausal breast cancer patients. *Gynecol Oncol* 1994; 55:185–190
10. Hahn LE, Giess CS, Bach AM, Tao Y, Baum HJ, Barakat RR. Endometrial thickness in tamoxifen-treated patients: correlation with clinical and pathologic findings. *AJR* 1997; 168:657–661
11. Fong K, Kung R, Lytwyn A, et al. Endometrial evaluation with transvaginal US and hysterosonography in asymptomatic postmenopausal women with breast cancer receiving tamoxifen. *Radiology* 2001; 220:765–773
12. Weaver J, McHugo JM, Clark TJ. Accuracy of transvaginal ultrasound in diagnosing endometrial pathology in women with post-menopausal bleeding on tamoxifen. *Br J Radiol* 2005; 78:394–397
13. Tepper R, Beyth Y, Altaras MM, et al. Value of sonohysterography in asymptomatic post-menopausal tamoxifen-treated patients. *Gynecol Oncol* 1997; 64:386–391
14. Hulka CA, Hall DA. Endometrial abnormalities associated with tamoxifen therapy for breast cancer: sonographic and pathologic correlation. *AJR* 1993; 160:809–812
15. Hahn, LE, Gretz EM, Bach AM, Francis SM. Sonohysterography for evaluation of the endometrium in women treated with tamoxifen. *AJR* 2001; 177:337–342
16. Cohen I, Beth Y, Tepper R, et al. Adenomyosis in postmenopausal breast cancer patients treated with tamoxifen: a new entity? *Gynecol Oncol* 1995; 58:86–91
17. McGonigle KF, Shaw SL, Vasilev SA, Odom-Maryon T, Soy S, Simpson JF. Abnormalities detected on transvaginal ultrasonography in tamoxifen-treated postmenopausal breast cancer patients may represent endometrial cystic atrophy. *Am J Obstet Gynecol* 1998; 178:1145–1150
18. Critchley HO, Warner P, Lee AJ, Brechin S, Guise J, Graham B. Evaluation of abnormal uterine bleeding: comparison of three outpatient procedures within cohorts defined by age and menopausal status. *Health Technol Assess* 2004; 8:1–139
19. De Kroon CD, de Bock GH, Dieben SW, Jansen FW. Saline contrast hysterosonography in abnormal uterine bleeding: a systematic review and meta-analysis. *Br J Obstet Gynaecol* 2003; 110:947–988
20. Van Dogen H, de Kroon CD, Jacobi CE, Trimbos JB, Jansen FW. Diagnostic hysteroscopy in abnormal uterine bleeding: a systematic review and meta-analysis. *Br J Obstet Gynaecol* 2007; 114:664–675
21. Lee SI. An imaging algorithm for evaluation of abnormal uterine bleeding: does sonohysterography play a role? *Menopause* 2007; 14:823–825
22. Leifer-Narin S, Ragavendra N, Parmenter EK, Grant EG. False normal appearance of the endometrium on conventional transvaginal sonography: comparison with saline hysterosonography. *AJR* 2002; 178:129–133
23. Clark TJ, Voit D, Gupta JK, Hyde C, Song F, Khan KS. Accuracy of hysteroscopy in the diagnosis of endometrial cancer and hyperplasia: a systematic quantitative review. *JAMA* 2002; 288:1610–1621
24. Smith-Bindman R, Kerlikowske K, Feldstein VA, et al. Endovaginal ultrasound to exclude endometrial cancer and other endometrial abnormalities. *JAMA* 1998; 280:1510–1517
25. Lin M, Gosink B, Wolf S, et al. Endometrial thickness after menopause: effect of hormone replacement. *Radiology* 1991; 180:427–432
26. Langer R, Pierce J, O'Hanlan K, et al. Transvaginal ultrasonography compared with endometrial biopsy for the detection of endometrial disease. *N Engl J Med* 1997; 337:1792–1798
27. Ascher SM, Imaoka I, Lage J. Tamoxifen-induced uterine abnormalities: the role of imaging. *Radiology* 2000; 214:29–38
28. Thurmond AS. *Abnormal vaginal bleeding. American College of Radiology appropriateness criteria: expert panel on women's imaging—women's work group.* Reston, VA: American College of Radiology, 1996:WI-4.1–WI-4.10

FOR YOUR INFORMATION

The reader's attention is directed to the SAM for this article, which appears on the following pages.

1.5 CME
1.0 SAM

AJR Integrative Imaging

LIFELONG LEARNING FOR RADIOLOGY

Algorithmic Workup of Abnormal Vaginal Bleeding with Endovaginal Sonography and Sonohysterography: *Self-Assessment Module*

Ann A. Shi[1,2] and Susanna I. Lee[1]

ABSTRACT

The educational objectives for this self-assessment module on endovaginal sonography and sonohysterography are for the participant to exercise, self-assess, and improve his or her understanding of the imaging evaluation of abnormal vaginal bleeding and to gain familiarity with the algorithm for the workup for endometrial disorders.

INTRODUCTION

This self-assessment module on the imaging evaluation of endometrial disorders has an educational component and a self-assessment component. The educational component consists of five required articles that the participant should read. The self-assessment component consists of 10 multiple-choice questions with solutions. All of these materials are available on the ARRS Website (www.arrs.org). To claim CME and SAM credit, each participant must enter his or her responses to the questions online.

EDUCATIONAL OBJECTIVES

By completing this educational activity the participant will:

A. Exercise, self-assess, and improve his or her understanding of the diagnostic features of endometrial disorders on endovaginal sonography and sonohysterography.

B. Appropriately use endovaginal sonography and sonohysterography to evaluate women with suspected endometrial disorders.

REQUIRED READING

1. Shi AA, Lee SI. Radiological reasoning: algorithmic workup of abnormal vaginal bleeding with endovaginal sonography and sonohysterography. *AJR* 2008; 191 [suppl]:S00–S00
2. Leifer-Narin S, Ragavendra N, Parmenter EK, Grant EG. False-normal appearance of the endometrium on conventional transvaginal sonography: comparison with saline hysterosonography. *AJR* 2002; 178:129–133
3. Jorizzo JR, Chen MYM, Riccio GJ. Endometrial polyps: sonohysterographic evaluation. *AJR* 2001; 176:617–621
4. Hahn LE, Giess CS, Bach AM, Tao Y, Baum HJ, Barakat RR. Endometrial thickness in tamoxifen-treated patients: correlation with clinical and pathologic findings. *AJR* 1997; 168:657–661
5. Hahn LE, Gretz EM, Bach AM, Francis SM. Sonohysterography for evaluation of the endometrium in women treated with tamoxifen. *AJR* 2001; 177:337–342

INSTRUCTIONS

1. Complete the required reading.
2. Visit www.arrs.org and select Publications/Journals/SAM Articles from the left-hand menu bar.
3. Using your member login, order the online SAM as directed.
4. Follow the online instructions for entering your responses to the self-assessment questions and complete the test by answering the questions online.

Keywords: algorithm, endometrium, premenopause, postmenopause, tamoxifen

DOI:10.2214/AJR.07.7114

Received July 17, 2008; accepted without revision July 17, 2008.

[1]Department of Radiology, Massachusetts General Hospital, Boston, MA.

[2]Present address: Department of Radiology, Montefiore Medical Center, 111 E 210th St., Bronx, NY 10467. Address correspondence to A. A. Shi (ashi@montefiore.org).

AJR 2008;191:SXX–SXX 0361–803X/08/1916–SXX

QUESTION 1

In a postmenopausal woman with abnormal vaginal bleeding who is not receiving hormone replacement therapy, which of the following endometrial thickness cutoff criteria is used to optimize accuracy for detecting cancer?

A. ≥ 4 mm.
B. ≥ 5 mm.
C. ≥ 6 mm.
D. ≥ 7 mm.
E. ≥ 8 mm.

QUESTION 2

In a postmenopausal woman with abnormal vaginal bleeding who is undergoing hormone replacement therapy, which of the following endometrial thickness cutoff criteria is used to optimize accuracy for detecting cancer?

A. ≥ 4 mm.
B. ≥ 5 mm.
C. ≥ 6 mm.
D. ≥ 7 mm.
E. ≥ 8 mm.

QUESTION 3

All of the following increase a woman's risk for endometrial hyperplasia and cancer EXCEPT which one?

A. Multiparity.
B. Obesity.
C. Diabetes.
D. Hypertension.
E. Tamoxifen exposure.

QUESTION 4

Which of the following statements regarding women receiving tamoxifen is FALSE?

A. Tamoxifen causes an increase in the prevalence of endometrial polyps, hyperplasia, and carcinoma.
B. Postmenopausal women taking tamoxifen usually show endometria that are thicker than in control subjects.
C. Endovaginal sonography is an accurate tool for diagnosing endometrial abnormalities in this patient population.
D. Subendometrial cystic changes can often simulate endometrial thickening on transvaginal sonography.
E. What should be considered normal endometrial thickness in asymptomatic women on tamoxifen is controversial.

QUESTION 5

The differential diagnosis of focal endometrial abnormality seen on sonohysterography includes which of the following?

A. Polyp.
B. Hyperplasia.
C. Carcinoma.
D. Subendometrial fibroid.
E. All of the above.

QUESTION 6

In differentiating focal endometrial disorders (e.g., polyp) from a subendometrial disorder (e.g., fibroid) on sonohysterography, which of the following statements is FALSE?

A. Polyps are frequently multifocal, whereas fibroids are usually solitary.
B. Polyps usually show a narrow base, whereas fibroids have a broad base of attachment to the uterine wall.
C. Polyps are typically echogenic like normal endometrium, whereas fibroids are typically hypoechoic like normal myometrium.
D. The normal endometrial lining underlies the base of a polyp, whereas it overlies the surface of a fibroid.
E. On color Doppler imaging, polyps show a single feeding vessel, whereas fibroids show a diffuse network of vessels.

QUESTION 7

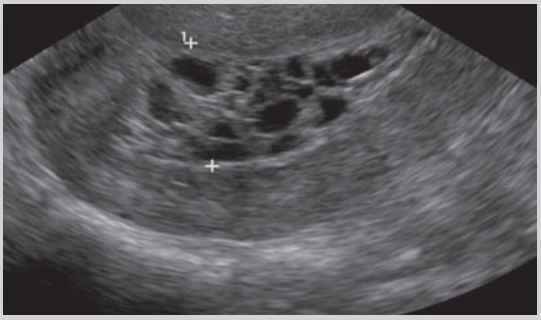

Figure 1 from an endovaginal sonography examination depicts the endometrium of a postmenopausal woman with vaginal bleeding and a history of several years of tamoxifen exposure. Which of the following is the LEAST LIKELY diagnosis?

A. Polyp.
B. Hyperplasia.
C. Carcinoma.
D. Subendometrial fibroid.
E. Subendometrial cysts.

QUESTION 8

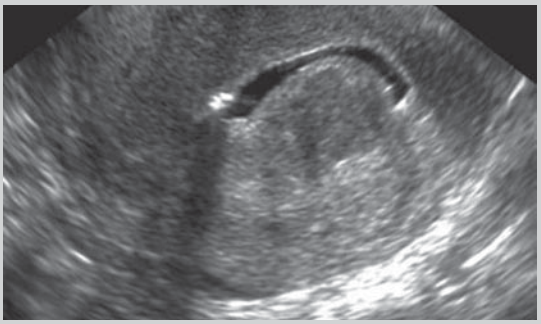

Figure 2 from a sonohysterography examination depicts a focal lesion. Which of the following is the MOST LIKELY diagnosis?

A. Polyp.
B. Hyperplasia.
C. Carcinoma.
D. Subendometrial fibroid.

QUESTION 9

Which of the following statements regarding diagnostic tools for endometrial disorders is TRUE?

A. Nonfocal biopsy to detect cancer should be performed after a negative workup for a focal abnormality.
B. Sonohysterography is more accurate than hysteroscopy for detecting focal endometrial disorders.
C. Endovaginal sonography is the most sensitive test for endometrial cancer detection in postmenopausal women.
D. Endovaginal sonography is highly sensitive in detecting endometrial disorders in the premenopausal woman.
E. MRI is replacing sonohysterography as a diagnostic tool for endometrial disorders.

QUESTION 10

Sonohysterography can be appropriately used in evaluating women with abnormal bleeding for all of the following purposes EXCEPT which one?

A. Evaluate endometrium not visualized or poorly visualized on endovaginal sonography.
B. Evaluate women with abnormal vaginal bleeding and normal findings on endovaginal sonography for underlying endometrial disorders.
C. Distinguish abnormality seen on endovaginal sonography as endometrial versus subendometrial.
D. Determine the size and location of focal lesions to plan hysteroscopic resection.
E. Characterize an endometrial lesion as benign or malignant.

Solution to Question 1

Meta-analysis of the diagnostic performance of endovaginal sonography in detecting endometrial cancer [1] has shown that a cutoff criterion of ≥ 5 mm results in 96% sensitivity and 92% specificity and shows optimum overall accuracy. **Option B is the best response.** Higher thickness cutoff criteria result in decreased sensitivity, whereas lower thickness cutoff criteria decrease specificity without significant increases in sensitivity. Options A, C, D, and E are not the best responses.

Solution to Question 2

Endovaginal sonography is the first-line screening technique for endometrial cancer in the workup of postmenopausal women receiving hormone replacement therapy. A thickness of 8 mm is considered the upper limit of normal if the patient is asymptomatic. However, if the patient reports postmenopausal bleeding, a thickness cutoff of ≥ 5 mm is used. **Option B is the best response.** Meta-analysis of the diagnostic performance of endovaginal sonography in detecting endometrial cancer [1] has shown that a cutoff criterion of ≥ 5 mm results in 96% sensitivity and 77% specificity and shows optimum overall accuracy. Higher-thickness cutoff criteria result in improved specificity but significant decreases in sensitivity, whereas lower-thickness cutoff criteria do not significantly increase sensitivity. Options A, C, D, and E are not the best responses.

Solution to Question 3

Endometrial hyperplasia and cancer are caused by unopposed estrogen stimulation. Risk factors include endogenous or exogenous exposure to estrogen, tamoxifen use, nulliparity, obesity, hypertension, and diabetes [2]. Options B, C, D, and E are not the best responses. Multiparity is not a risk factor for endometrial hyperplasia and cancer. **Option A is the best response.**

Solution to Question 4

Tamoxifen has a weak estrogenic effect in the uterus and causes an increased prevalence of endometrial polyps, hyperplasia, and carcinoma. Option A is not the best response. Subendometrial cysts, a finding associated with tamoxifen exposure, can often simulate endometrial thickening on transvaginal sonography, decreasing its diagnostic accuracy. Option D is not the best response. Furthermore, several disorders, such as polyps and carcinoma, may coexist, limiting the usefulness of endovaginal sonography in the diagnosis of specific abnormality [3]. **Option C, which is not true, is the best response.** Sonohysterography may help differentiate subendometrial from endometrial abnormalities and guide proper diagnostic workup. Postmenopausal women taking tamoxifen often have endometria that are thicker than those of control subjects [4], and most of them are asymptomatic. Option B is not the best response. What constitutes the normal endometrial thickness for this group of patients is con-

troversial, with 5–8 mm having been proposed [5–7]. Option E is not the best response.

Solution to Question 5

Polyps are a common cause of focal endometrial thickening. On sonohysterography, polyps appear as echogenic, smooth, intracavitary masses outlined by fluid. The point of attachment does not disrupt the endometrial lining. Cystic spaces corresponding to dilated glands filled with proteinaceous fluid, or heterogeneous echotexture as a result of hemorrhage, infarction, or inflammation, can be seen. Although diffuse thickening is the most common appearance of endometrial hyperplasia and cancer, both can be focal on occasion. Subendometrial fibroids can usually but not always be distinguished from endometrial disorders by the appearance on sonohysterography. Subendometrial fibroids are typically hypoechoic, well-defined solid masses that show acoustic attenuation. Most important, they show an overlying layer of echogenic endometrium [8]. Options A–D are all correct, so **option E is the best response.**

Solution to Question 6

On sonohysterography, endometrial polyps are typically echogenic, like normal endometrium, and show a narrow attachment to the normal endometrial lining at its base [9]. Option B is not the best response. A single feeding vessel is sometimes seen on color Doppler sonography. In contrast, subendometrial fibroids are typically hypoechoic, like normal myometrium, and show a broad base of attachment to the myometrial wall with the normal endometrial lining overlying its surface [8]. Option C is not the best response. Fibroids show a hypervascular network of vessels on color Doppler sonography [10]. Option E is not the best response. The key to differentiating the two entities is ascertaining the location of the endometrial lining with regard to the lesion. The normal endometrial lining underlies the base of a polyp, whereas it overlies the surface of a fibroid. Option D is not the best response. Whether a focal lesion is solitary or multiple on sonohysterography does not distinguish between an endometrial or subendometrial process. **Option A, which is not true, is the best response.**

Solution to Question 7

The endometrium is abnormally thick, measuring 2.1 cm, and contains multiple cysts. Chronic exposure to tamoxifen results in an increased likelihood of endometrial disorders such as polyps, hyperplasia, and carcinoma [4]. Options A, B, and C are not the best responses. These disorders are often detected as abnormal endometrial thickening, sometimes with cystic changes. In addition, patients taking tamoxifen can show subendometrial cysts that mimic endometrial thickening on transvaginal sonography [11]. Option E is not the best response. The appearance of this endometrium is least consistent with an underlying submucosal fibroid that typically appears hypoechoic, homogeneously solid, and well circumscribed. **Option D is the best response.**

Solution to Question 8

The lesion is a hypoechoic, well-defined solid mass with a broad base of attachment. Most important, it shows an overlying layer of echogenic endometrium, indicating that this lesion is subendometrial in location. This appearance is most consistent with a subendometrial fibroid. **Option D is the best response.** Polyp, hyperplasia, and carcinoma are endometrial disorders. Options A, B, and C are not the best responses.

Solution to Question 9

Because endometrial cancer and hyperplasia, which are nonfocal abnormalities, constitute the only potentially life-threatening endometrial disorders, endovaginal sonography, followed by nonfocal endometrial biopsy when indicated, should be performed early in the diagnostic workup of abnormal bleeding to evaluate for these disorders. Only after these prove negative should focal, more likely benign causes be sought to explain the bleeding. Option A is not the best response. Sonohysterography and hysteroscopy are two methods for detecting focal lesions and are similar in sensitivity and specificity [12, 13]. Option B is not the best response. Endovaginal sonography is highly effective in screening for cancer in the postmenopausal population using a thickness cutoff of ≥ 5 mm. **Option C is the best response.** In the premenopausal population, endovaginal sonography is a useful tool for identifying mural abnormalities such as fibroids and adenomyosis. However, its performance in detecting endometrial disorders is suboptimal, with a sensitivity of 67% and a specificity of 75% [14]. Option D is not the best response. The role of MRI in the workup of abnormal vaginal bleeding is limited. Option E is not the best response.

Solution to Question 10

Sonohysterography distinguishes endometrial from subendometrial abnormalities. Options C is not the best response. Once a lesion has been characterized as endometrial, imaging cannot reliably exclude malignancy. Focal endometrial hyperplasia or carcinoma can mimic a sessile polyp, and foci of atypical hyperplasia are sometimes found in polyps. Thus, endometrial lesions should undergo histologic evaluation. **Option E, which is not true, is the best response.** Sonohysterography is useful for detecting, localizing, and sizing focal endometrial disorders before hysteroscopic resection. Option D is not the best response. It is more sensitive than endovaginal sonography for detecting focal endometrial disorders, especially in premenopausal women or those who have undergone long-term tamoxifen therapy [15]. Option B is not the best response. Sonohysterography can be used to evaluate the endometrium when endovaginal sonography fails to adequately visualize it, often because of distortion by fibroids. Option A is not the best response.

References

1. Smith-Bindman R, Kerlikowske K, Fedlstein VA, et al. Endovaginal ultrasound to exclude endometrial cancer and other endometrial abnormalities. *JAMA* 1998; 280:1510–1517
2. Creasman W. Endometrial carcinoma. emedicine from WebMD Website. emedicine.com/med/topic674.htm. Accessed August 12, 2008
3. Hulka CA, Hall DA. Endometrial abnormalities associated with tamoxifen therapy for breast cancer: sonographic and pathologic correlation. *AJR* 1993; 160:809–812
4. Cohen I, Rosen DJ, Shapira J, et al. Endometrial changes with tamoxifen: comparison between tamoxifen-treated and nontreated asymptomatic, postmenopausal breast cancer patients. *Gynecol Oncol* 1994; 55:185–190
5. Fong K, Kung R, Lytwyn A, et al. Endometrial evaluation with transvaginal US and hysterosonography in asymptomatic postmenopausal women with breast cancer receiving tamoxifen. *Radiology* 2001; 220:765–773
6. Weaver J, McHugo JM, Clark TJ. Accuracy of transvaginal ultrasound in diagnosing endometrial pathology in women with post-menopausal bleeding on tamoxifen. *Br J Radiol* 2005; 78:394–397
7. Hulka CA, Hall DA. Endometrial abnormalities associated with tamoxifen therapy for breast cancer: sonographic and pathologic correlation. *AJR* 1993; 160:809–812
8. Davis PC, O'Neill MJ, Yoder IC, Lee SI, Mueller PR. Sonohysterographic findings of endometrial and subendometrial conditions. *RadioGraphics* 2002; 22:803–816
9. Jorizzo JR, Chen MYM, Riccio GJ. Endometrial polyps: sonohysterographic evaluation. *AJR* 2001; 176:617–621
10. Tamura-Sadamori R, Emoto M, Naganuma Y, Hachisuga T, Kawarabayashi T. The sonohysterographic difference in submucosal uterine fibroids and endometrial polyps treated by hysteroscopic surgery. *J Ultrasound Med* 2007; 26:941–946
11. Fong K, Kung R, Lytwyn A, et al. Endometrial evaluation with transvaginal US and hysterosonography in asymptomatic postmenopausal women with breast cancer receiving tamoxifen. *Radiology* 2001; 220:765–773
12. Ke Kroon CD, de Bock GH, Dieben SW, Jansen FW. Saline contrast hysterosonography in abnormal uterine bleeding: a systematic review and meta-analysis. *Br J Obstet Gynaecol* 2003; 110:947–988
13. Van Dogen H, de Kroon CD, Jacobi CE, Trimbos JB, Jansen FW. Diagnostic hysteroscopy in abnormal uterine bleeding: a systematic review and meta-analysis. *Br J Obstet Gynaecol* 2007; 114:664–675
14. Smith P, Bakos O, Heimer G, Ulmsten U. Transvaginal ultrasound for identifying endometrial abnormality. *Acta Obstet Gynecol Scand* 1991; 70:591–594
15. Leifer-Narin S, Ragavendra N, Parmenter EK, Grant EG. False-normal appearance of the endometrium on conventional transvaginal sonography: comparison with saline hysterosonography. *AJR* 2002; 178:129–133

FOR YOUR INFORMATION

The reader's attention is directed to the Radiological Reasoning article on which this SAM is based, which appears on the preceding pages.

AJR Teaching File: Profuse Vaginal Bleeding in a Patient with a History of Induced Abortion

Jose Maldonado[1], Constantino Perez, and Wilma Rodriguez

Case History

A 21-year-old woman who underwent an induced abortion 7 weeks earlier presented to an outside clinic with a 3-week history of profuse vaginal bleeding and symptomatic anemia. Serum β-hCG measurements were negative. The patient was transferred to our institution for definitive management.

Radiologic Description

Endovaginal sagittal gray-scale sonography of the uterus (Fig. 1A) shows parenchymal inhomogeneity by the fundus with several interspersed sonolucent spaces of varying size. Color Doppler sonography (Fig. 1B) reveals the hypervascular nature of the latter. A transverse image (Fig. 1C) better shows the extent of the vascular lesion.

Four days later, at our institution, follow-up endovaginal sagittal gray-scale sonography (Fig. 1D) shows rather unremarkable and homogeneous uterine parenchyma. Transabdominal color Doppler sonography (Fig. 1E) at the same level nonetheless once again shows persistent hypervascularity and turbulent flow in the myometrium. Endovaginal transverse oblique duplex Doppler sonography (Fig. 1F) shows low-resistance, high-velocity flow with a resistive index (RI) of 0.43, a pulsatility index (PI) of 0.68, and a peak systolic velocity of 35 cm/s.

Coronal fat-suppressed fast spin-echo T2-weighted (TR/TE, 5,250/67.6) and contrast-enhanced fat-suppressed coronal fast spin-echo T1-weighted (417/10.8) MR sequences (Figs. 1G and 1H) show multiple serpiginous flow-related signal voids in the myometrium, corresponding to the sonographic findings. A fluid-sensitive coronal STIR (3,250/57.4; inversion time, 150 milliseconds) MR sequence better shows associated asymmetric prominence of the contiguous parametrial vessels on the right (Fig. 1I).

Selective catheterization of the anterior division of the right internal iliac artery (Fig. 1J) shows hypertrophied uterine artery end branches opacifying a hypervascular tangle of vessels. The contralateral side is unremarkable. Transcatheter embolotherapy at the anterior division of the right internal iliac artery is performed successfully. Vaginal bleeding stopped immediately. The patient tolerated the procedure well with minimal discomfort and no complications and was discharged 2 days later.

Differential Diagnosis

The main differential diagnosis of uterine vascular lesions includes retained products of conception, a gynecologic neoplasm such as gestational trophoblastic disease (GTD), arteriovenous malformation (AVM), uterine artery pseudoaneurysm, and direct arterial branch injury.

Diagnosis

The diagnosis is acquired uterine AVM.

Commentary

In the clinical setting of vaginal bleeding, one can use clinical history and laboratory data to narrow the diagnosis and determine the best course of management before initiating imaging studies. For example, GTD and retained products of conception are conditions known to produce arteriovenous shunting that can be difficult to distinguish from uterine AVMs by imaging studies alone. However, these pregnancy-related entities can be diagnosed with the help of serum hCG measurements. Distinguishing between these conditions and uterine AVMs is critical because the latter can be treated safely and effectively with percutaneous transcatheter embolization but may be complicated by surgical intervention and curettage with heavy, even life-threatening, bleeding [1, 2].

An AVM can be defined as a tangle of abnormal arteriovenous connections lacking an intervening capillary network on histopathologic examination. Congenital AVMs arise as a result of a defect in embryonic vascular differentiation or of developmental arrest. They may extend beyond the uterus and can grow as pregnancy progresses. Acquired AVMs, on the other hand, are usually secondary to uterine trauma (e.g., D&C, therapeutic abortion, uterine surgery, intrauterine devices) or GTD [3, 4].

Keywords: angiography, arteriovenous malformation, sonography, uterus, vascular system

DOI:10.2214/AJR.07.7044

Received September 30, 2007; accepted after revision February 12, 2008.

[1]All authors: Department of Radiology, Medical Sciences Campus, University of Puerto Rico, PO Box 365067, San Juan, PR 00936-5067. Address correspondence to J. Maldonado (maldonadojose@email.com).

AJR 2008;191:SXX–SXX 0361–803X/08/1916–SXX

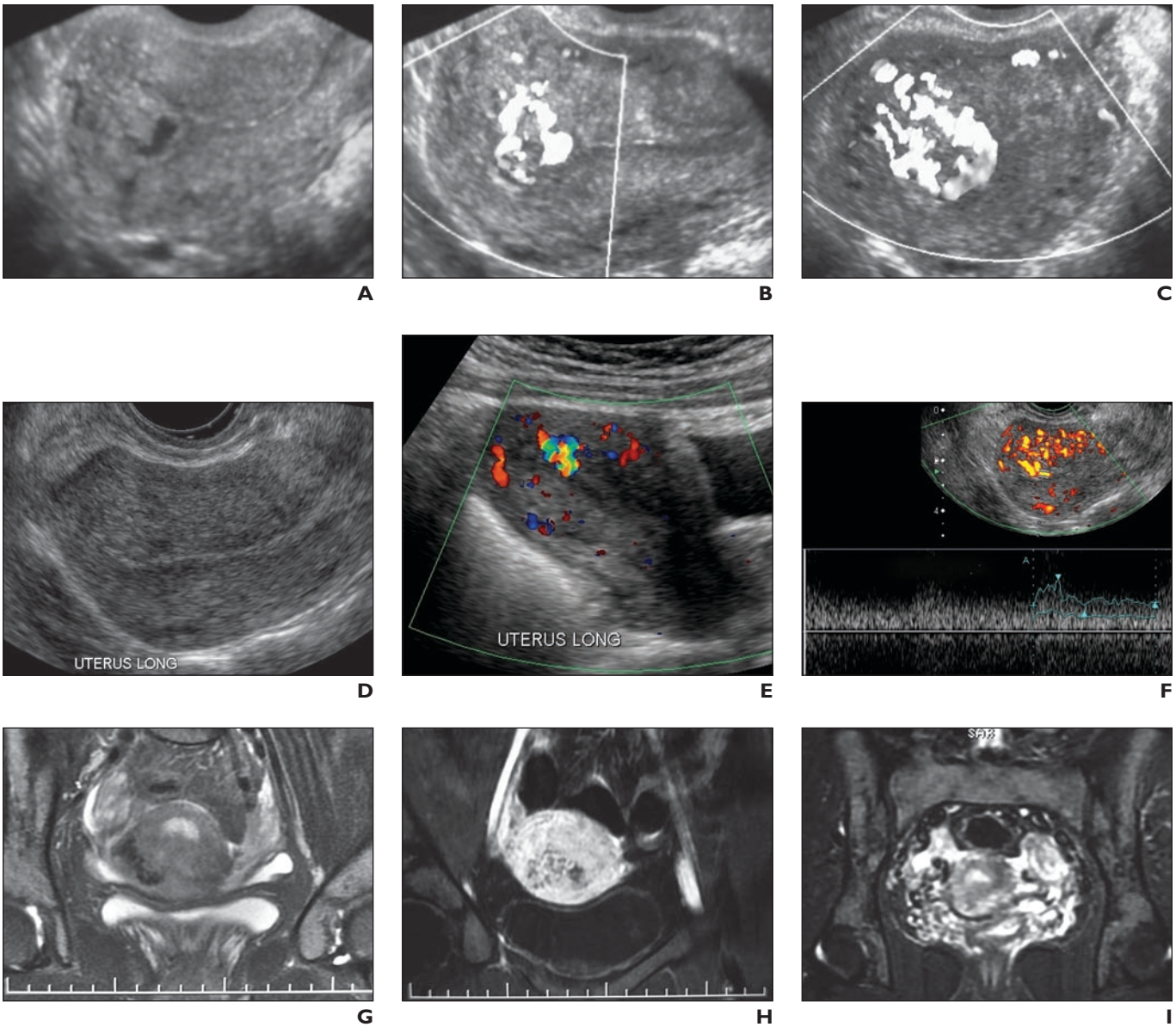

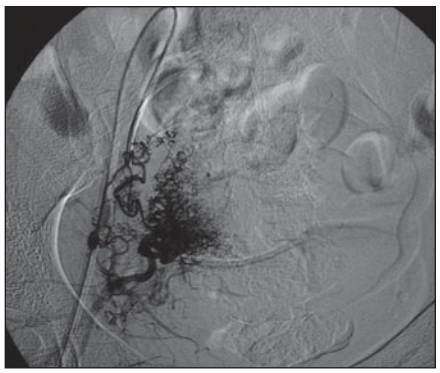

Fig. 1—21-year-old woman who underwent induced abortion 7 weeks earlier. Patient presented to outside clinic with 3-week history of profuse vaginal bleeding and symptomatic anemia.
A, Endovaginal sagittal gray-scale sonogram of uterus shows parenchymal inhomogeneity next to fundus and several interspersed sonolucent spaces of varying sizes.
B, Endovaginal color Doppler sonogram (shown here in black and white) reveals hypervascular nature of sonolucent spaces.
C, Endovaginal transverse color Doppler sonogram (shown here in black and white) better shows extent of vascular lesion.
D, Follow-up endovaginal sagittal gray-scale sonogram shows rather unremarkable and homogeneous uterine parenchyma.
E, Transabdominal color Doppler sonogram at same level as **D** also shows persistent hypervascularity and turbulent flow in myometrium.
F, Endovaginal transverse oblique duplex Doppler sonogram shows low-resistance, high-velocity flow with resistive index of 0.43, pulsatility index of 0.68, and peak systolic velocity of 35 cm/s.
G, Coronal fat-suppressed fast spin-echo T2-weighted (TR/TE, 5,250/67.6) image shows multiple serpiginous flow-related signal voids in myometrium, corresponding to sonographic findings.
H, Contrast-enhanced fat-suppressed coronal fast spin-echo T1-weighted (417/10.8) image during arterial phase also shows multiple serpiginous flow-related signal voids in myometrium, corresponding to sonographic findings.
I, Fluid-sensitive coronal STIR (3,250/57.4; inversion time, 150 milliseconds) image better shows associated asymmetric prominence of contiguous parametrial vessels on right.
J, Frontal digital subtraction angiography of selective catheterization of anterior division of right internal iliac artery shows hypertrophied uterine artery end branches opacifying hypervascular tangle of vessels.

Uterine AVMs are usually evaluated initially with sonography. Gray-scale sonography may show an inhomogeneous myometrium with hypoechogenic tubular structures. These findings are nonspecific and in some cases can be inconspicuous and difficult to appreciate. Color Doppler sonographic features are invariably more extensive than those of gray-scale sonography and are essential for the complete radiologic evaluation of uterine AVMs. Hypervascular areas with a color mosaic of aliasing and flow reversal are characteristic. Spectral sonographic analysis provides additional information, showing a low-resistance, high-velocity flow, with RI values ranging from 0.25 to 0.55 and PI values from 0.3 to 0.6. These spectral sonographic findings are similar for AVMs found elsewhere in the body [1, 5].

MRI serves to support the radiologic impression of AVM obtained by sonography. It is helpful in determining the magnitude of the vascular malformation, particularly if extrauterine extension is suspected. MR angiographic sequences are well suited for these purposes, allowing preinterventional planning. Moreover, additional pelvic disorders may be identified and better characterized with MRI. Serpiginous flow-related signal voids corresponding to the myometrial hypervascular areas on color Doppler sonography are characteristic of uterine AVMs. Prominent parametrial vessels and disruption of the junctional zones may also be present [1].

Angiography is considered the reference standard for the definitive diagnosis of AVMs, which appear as a markedly opacified vascular tangle, typically with early venous filling. However, angiography is an invasive procedure that should be reserved for patients in whom surgical intervention or therapeutic transcatheter embolization is contemplated. The angiographic goals are to define the vascular anatomy, assess the extent of the vascular malformation, and identify the feeding vessels. As in the management of other gynecologic disorders, the typical interventional approach starts with initial pelvic angiography using the Seldinger technique through the common femoral artery. Selective internal iliac angiography on the side affected is then performed. Some small AVMs are shown only by superselective catheterization of the uterine arteries. This can be accomplished with an angled 5-French catheter; however, 4-French hydrophilic microcatheters or 3-French microcatheters may be necessary to prevent spasm. Even after unilateral uterine artery embolization, we routinely reexamine the contralateral arteries. In some cases, previously inconspicuous feeding arteries may then be identified to advantage.

Patients with AVMs commonly present with vaginal bleeding after a miscarriage, uterine surgery, or curettage. Other symptoms include abdominal pain, dyspareunia, and anemia secondary to blood loss, which can be intermittent or profuse. Traditionally, the treatment of AVMs had been hysterectomy and uterine artery ligation. Intrauterine tamponade with a Foley bulb can be used as a temporizing measure. More recently, percutaneous transcatheter embolization has gained wide acceptance as a safe and effective alternate treatment. This procedure preserves uterine function and the possibility of future childbearing. Its clinical success rate after one to two embolization procedures is 93–96%, and its complication rate is 4% [3, 6, 7].

Several potential embolic agents are available to the interventional radiologist, including absorbable gelatin sponge, glue, microparticles, coils, or a combination of these agents. As previously stated, our patient was observed for 2 days and later discharged after an uneventful recovery. Nonetheless, adverse events after uterine artery percutaneous transcatheter embolization may be observed, most of which are minor. Patients often experience pelvic pain and nausea for 12–24 hours after the procedure, which gradually decreases in the next 5–7 days. Severe complications are rare and include uterine necrosis, sepsis, and lethal pulmonary embolism [8].

Clearly, in a patient presenting with vaginal bleeding and negative results of hCG, the diagnosis of AVM should be considered, particularly if a history of uterine instrumentation is elicited. Other uterine vascular abnormalities, including pseudoaneurysm and direct arterial branch injury, may have a similar clinical history and presentation. Imaging studies can reliably distinguish these traumatic vascular abnormalities from AVMs. A uterine pseudoaneurysm is characterized sonographically by a cystic structure that on duplex Doppler sonography shows turbulent arterial flow in a blood-filled sac and to-and-fro flow in the neck. In direct arterial branch injury, a heterogeneous intraparenchymal or cavitary hematoma may be shown, with slowly moving blood in the endometrial canal. Evidence of contrast extravasation in angiography is confirmatory. Both of these conditions are also amenable to percutaneous transcatheter embolization and could likewise be complicated by surgical intervention [8].

In addition to aiding in the diagnosis of AVMs, duplex Doppler sonography may be useful in distinguishing between low- and high-risk patients. After studying 30 patients with uterine vascular malformations, Timmerman et al. [4] noted that peak systolic velocity of ≥ 83 cm/s was associated with an increased likelihood of further treatment such as embolization, whereas no vascular malformation with a peak systolic velocity value < 39 cm/s required embolization. Maleux et al. [6], on the other hand, used the sonographic findings in patients with AVMs to plan the radiologic interventional approach. Specifically, uni- or bilateral embolization was performed, depending on whether the hypervascular area was unilateral, bilateral, or extended over the midline, as shown on sonography. By virtue of its lack of ionizing radiation, low cost, and availability, sonography is the preferred imaging technique for following up patients after treatment. Therefore, as in many other gynecologic conditions, the role of sonography in the management of uterine AVMs is often pivotal.

Objective

The educational objective of this article is to describe the imaging features and therapeutic options in a patient with

acquired uterine vascular malformation presenting with profuse vaginal bleeding.

Conclusion

In a patient presenting with vaginal bleeding, it is important for radiologists to evaluate the possibility of a uterine AVM before surgical intervention is considered. Color Doppler sonography is essential for the diagnosis of uterine AVMs. Angiography confirms the diagnosis and allows percutaneous transcatheter embolotherapy, which is a safe and highly effective treatment option.

References

1. Huang MW, Muradali D, Thurston WA, Burns PN, Wilson SR. Uterine arteriovenous malformations: gray-scale and Doppler US features with MR imaging correlation. *Radiology* 1998; 206:115–123
2. Jain K, Fogata M. Retained products of conception mimicking a large endometrial AVM: complete resolution following spontaneous abortion. *J Clin Ultrasound* 2007; 35:42–47
3. Ghai S, Rajan DK, Asch MR, Muradali D, Simons ME, TerBrugge KG. Efficacy of embolization in traumatic uterine vascular malformations. *J Vasc Interv Radiol* 2003; 14:1401–1408
4. Timmerman D, Wauters J, Van Calenbergh S, et al. Color Doppler imaging is a valuable tool for the diagnosis and management of uterine vascular malformations. *Ultrasound Obstet Gynecol* 2003; 21:570–577
5. Polat P, Suma S, Kantarcy M, Alper F, Levent A. Color Doppler US in the evaluation of uterine vascular abnormalities. *RadioGraphics* 2002; 22:47–53
6. Maleux G, Timmerman D, Heye S, Wilms G. Acquired uterine vascular malformations: radiological and clinical outcome after transcatheter embolotherapy. *Eur Radiol* 2006; 16:299–306. Epub 2005 Jun 24
7. Kim D, Baer SD. Interventional radiology in management of obstetrical and gynecological disorders. UpToDate online (15.1). www.uptodate.com/online/content/topic.do?topicKey=gyn_proc/7850. Accessed August 24, 2008
8. Kwon JH, Kim GS. Obstetric iatrogenic arterial injuries of the uterus: diagnosis with US and treatment with transcatheter arterial embolization. *RadioGraphics* 2002; 22:35–46