

Coronavirus Disease 2019 (COVID-19): A Systematic Review of Imaging Findings in 919 Patients

Sana Salehi¹
Aidin Abedi
Sudheer Balakrishnan
Ali Gholamrezanezhad

OBJECTIVE. Available information on CT features of the 2019 novel coronavirus disease (COVID-19) is scattered in different publications, and a cohesive literature review has yet to be compiled.

MATERIALS AND METHODS. This article includes a systematic literature search of PubMed, Embase (Elsevier), Google Scholar, and the World Health Organization database.

RESULTS. Known features of COVID-19 on initial CT include bilateral multilobar ground-glass opacification (GGO) with a peripheral or posterior distribution, mainly in the lower lobes and less frequently within the right middle lobe. Atypical initial imaging presentation of consolidative opacities superimposed on GGO may be found in a smaller number of cases, mainly in the elderly population. Septal thickening, bronchiectasis, pleural thickening, and subpleural involvement are some of the less common findings, mainly in the later stages of the disease. Pleural effusion, pericardial effusion, lymphadenopathy, cavitation, CT halo sign, and pneumothorax are uncommon but may be seen with disease progression. Follow-up CT in the intermediate stage of disease shows an increase in the number and size of GGOs and progressive transformation of GGO into multifocal consolidative opacities, septal thickening, and development of a crazy paving pattern, with the greatest severity of CT findings visible around day 10 after the symptom onset. Acute respiratory distress syndrome is the most common indication for transferring patients with COVID-19 to the ICU and the major cause of death in this patient population. Imaging patterns corresponding to clinical improvement usually occur after week 2 of the disease and include gradual resolution of consolidative opacities and decrease in the number of lesions and involved lobes.

CONCLUSION. This systematic review of current literature on COVID-19 provides insight into the initial and follow-up CT characteristics of the disease.

Keywords: coronavirus, COVID-19, CT scan, influenza, 2019-nCoV, outbreak, pneumonia, radiology, systematic review, viral

doi.org/10.2214/AJR.20.23034

S. Salehi and A. Abedi contributed equally to this study.

Received February 27, 2020; accepted without revision February 29, 2020.

¹All authors: Department of Radiology, Keck School of Medicine, University of Southern California, 1500 San Pablo St, Los Angeles, CA 90033. Address correspondence to A. Gholamrezanezhad (ali.gholamrezanezhad@med.usc.edu).

Supplemental Data

Available online at www.ajronline.org.

AJR 2020; 215:1–7

ISSN-L 0361–803X/20/2155–1

© American Roentgen Ray Society

Several cases of pneumonia with an unidentified origin emerged from Wuhan, China, and were reported to the World Health Organization (WHO) on December 31, 2019 [1]. On January 7, 2020, the 2019 novel coronavirus (2019-nCoV; later renamed severe acute respiratory syndrome coronavirus 2 [SARS-CoV-2]) was confirmed as the cause of these reported cases, and the outbreak was subsequently named coronavirus disease (COVID-19) [2]. The WHO declared the outbreak a global health emergency on January 30, 2020. As of February 20, 2020, a total of 75,761 cases and 2130 deaths had been reported in more than 30 countries [3].

Because of the primary involvement of the respiratory system, chest CT is strongly recommended in suspected COVID-19 cases, for both initial evaluation and follow-up [4].

Chest radiographs are of little diagnostic value in early stages, whereas CT findings may be present even before symptom onset [5, 6]. In the intermediate to advanced stages of the disease, chest radiographs may show progression of features of acute respiratory distress syndrome (ARDS) (Fig. 1). Furthermore, CT findings have proven to be diagnostic in a number of cases with an initial false-negative reverse transcription polymerase chain reaction (RT-PCR) screening test [7, 8]. An assessment of 41 patients with a laboratory-confirmed COVID-19 diagnosis revealed abnormal chest CT findings in all cases [9]. Subsequently, multiple case series were published, aiming to define the CT features of COVID-19 pneumonia.

With growing global concerns about the COVID-19 outbreak, a comprehensive understanding of the diagnostic imaging hallmarks, atypical features, and evolution of

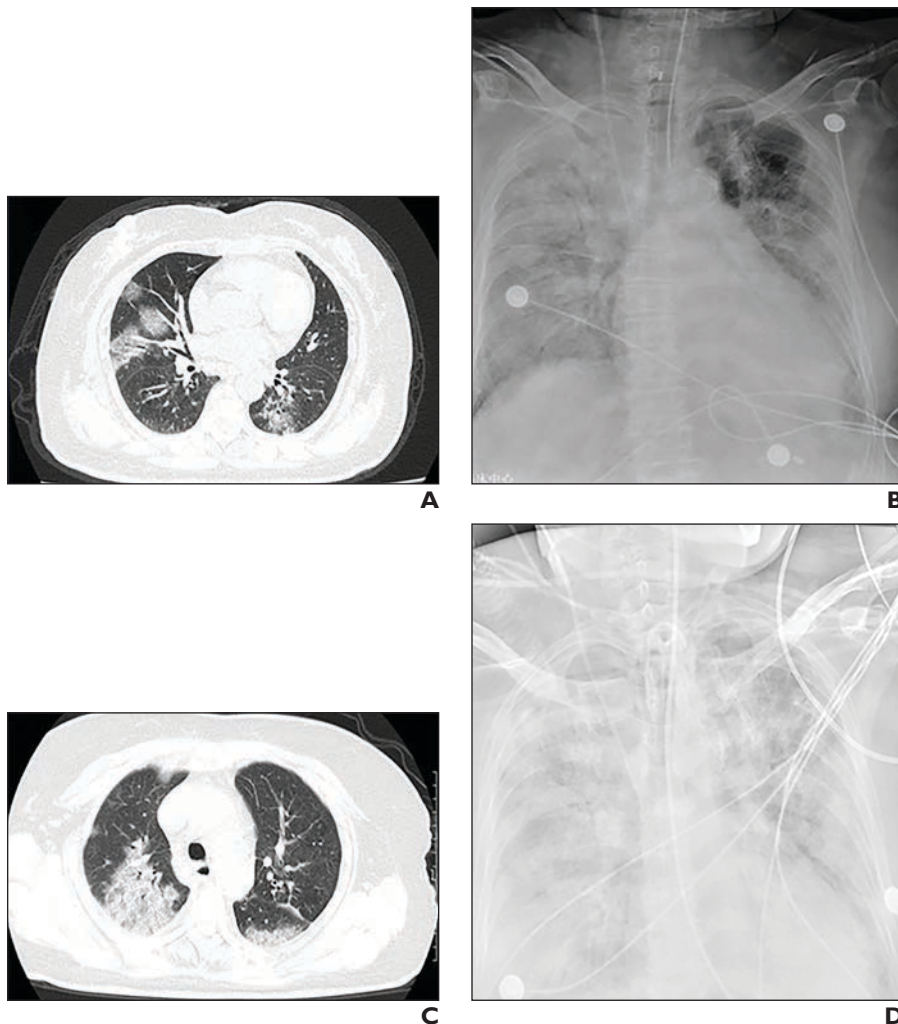


Fig. 1—79-year-old woman who presented with chest pain, cough, and fever for 3 days. Coronavirus disease (COVID-19) had recently been diagnosed in two of her household members. Patient developed acute respiratory distress syndrome within subsequent few days and died 11 days after admission. (Courtesy of Song F, Shanghai Public Health Clinical Center, Shanghai, China)
A and B, CT image (**A**) and chest radiograph (**B**) show ground glass opacification (GGO) on day 1.
C and D, CT image (**C**) and chest radiograph (**D**) obtained on day 4 show GGO has progressed to airspace consolidation.

chest imaging findings is essential for effective patient management and treatment. However, the available information is scattered in different publications, and a comprehensive literature review has yet to be performed. Therefore, this systematic review was compiled to identify the CT characteristics of this life-threatening and rapidly spreading viral pneumonia, summarize key imaging findings in different stages of the disease, and define the evolution of CT findings associated with disease progression or clinical improvement. We also aim to investigate how CT findings correlate with patients' age, severity of clinical symptoms, laboratory testing, and disease prognosis.

Materials and Methods

Literature Search

A systematic literature search of PubMed and Embase (Elsevier) databases was performed on February 12, 2020, and updated on February 19, 2020, using the keywords “coronavirus,” “nCoV,” “2019-nCoV,” and “COVID-19.” Considering the urgency of the topic and to increase the sensitivity of the search, a gray literature search was performed using the same keywords on Google Scholar to capture the most recently published articles. Furthermore, the WHO database of publications on novel coronavirus was screened for potentially relevant publications [10]. Additional articles were retrieved by screening the reference lists of the included studies and from the archives of the review-

ers. One of the reviewers with experience in database searches designed the search strategy, which was subsequently revised by other reviewers. With consideration of the date of the earliest confirmed reports of COVID-19, the searches were limited to articles published in 2020. Because of the large number of records identified from the gray literature, the Google Scholar search was limited to titles. However, no additional limits were applied in the PubMed or Embase search.

Eligibility Criteria and Study Selection

To be included in the final review, the articles needed to be published in English, include patients diagnosed with the recent coronavirus outbreak (COVID-19), and report CT findings. Studies pertaining to other coronavirus-related illnesses, such as Middle East respiratory syndrome (MERS) were excluded. Two reviewers independently screened the titles and abstracts according to these eligibility criteria [11] (Fig. 2). Disagreements were discussed with other reviewers and subsequently resolved via consensus.

Risk of Bias

Two reviewers independently rated the quality of included studies using the National Institutes of Health Quality Assessment Tool for Case Series Studies [12] (Table 1).

Data Extraction and Synthesis

The following data categories were collected when available: study design, country, patient demographics, and chest CT findings. One of the reviewers performed the data extraction, and the other reviewer assessed the accuracy of the extracted data. When studies contained sufficient granular data, findings such as the number of involved pulmonary lobes and general pattern of lesions were combined across the studies. A meta-analysis was planned to assess the association of various imaging findings with demographic data, outcomes, and disease characteristics; however, this analysis was omitted because of the lack of sufficient data.

Results

Overview of the Included Studies

After removing the duplicate search records, a total of 2679 records were identified from the electronic searches (Fig. 2). After the search records were screened, 30 studies consisting of 19 case series and 11 case reports with a total of 919 patients were included in the final review. Characteristics of the included studies are presented in Table S1, which can be viewed in the *AJR* electronic supplement to this article (available

Systematic Review of COVID-19 Imaging Findings

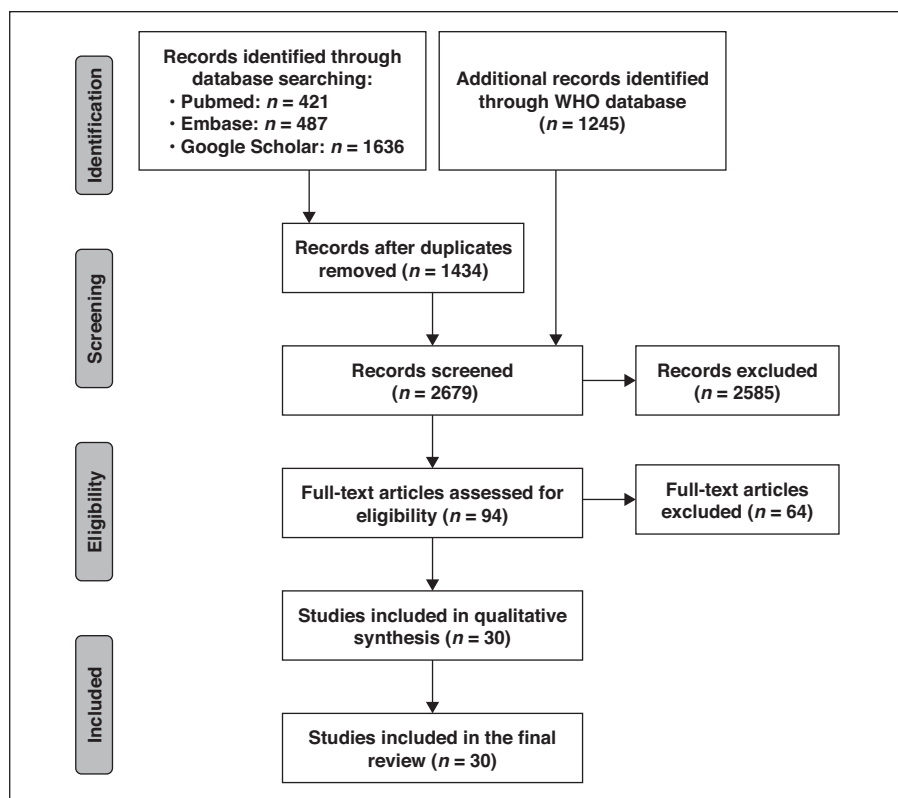


Fig. 2—Preferred reporting items for systematic reviews and meta-analyses (PRISMA) flow diagram shows study selection process. Embase is a product of Elsevier. WHO = World Health Organization. Adapted from Moher et al. (doi.org/10.1371/journal.pmed.1000097) ©2009, under terms of Creative Commons Attribution 4.0 International Licence (creativecommons.org/licenses/by/4.0/legalcode).

at www.ajronline.org). CT manifestations of COVID-19 in pediatric cases were rarely reported. All the included studies were from China, except for one case reported from Korea. Imaging modality was chest CT in all studies, although nonspecific chest radiography findings were reported occasionally. Methodologic quality of the studies was generally fair, with exception of one study that was rated as poor because of insufficient data (Table 1).

Chest CT Manifestation

A wide variety of CT findings in COVID-19 were reported in several studies (Table S1). After combining the available data, we found the characteristic patterns and distribution of CT manifestations: ground glass opacification (GGO) (88.0%), bilateral involvement (87.5%), peripheral distribution (76.0%), and multilobar (more than one lobe) involvement (78.8%) (Table 2). Isolated GGO or a combination of GGO and consolidative opacities were some of the most common CT findings. Other CT findings included in-

terlobular septal thickening, bronchiectasis, pleural thickening, and subpleural involvement, with various rates across the studies [5, 13–18]. Pleural effusion, pericardial effusion, lymphadenopathy, cavitation, CT halo sign, and pneumothorax were less common or rare [19–21].

In a prospective case series of 41 admitted patients, CT abnormalities suggestive of pneumonia were reported in 100% of the patients, among which 98% of cases showed bilateral lung involvement [9]. Among patients admitted to the ICU, the most common CT findings were multiple lobar and subsegmental consolidations [9]. In another study of 51 patients with confirmed COVID-19, 1324 lung lesions were detected on chest CT within 1 to 14 days (median, 4 days) of symptom onset [19]. The most common CT findings seen in these patients were (in respective order): isolated GGO, GGO with reticular or interlobular septal thickening, and GGO in combination with consolidative opacities. Air bronchograms were reported in 80% of these patients [19]. Involvement of multiple lobes,

particularly the lower lobes with a peripheral or posterior distribution (or both), were reported in the majority of these patients [19].

In another study, Chung et al. [22] characterized the CT manifestations of COVID-19 pneumonia in 21 patients and reported bilateral lung involvement in 76% and peripheral airspace opacities in one-third of the cases at presentation. More than half of their patients showed GGO without consolidative opacities, whereas 29% showed GGO in addition to consolidative opacities at presentation. They characterized the pattern of the lesions as round in 33%, predominantly linear in 14%, and crazy paving pattern in 19%. In 38% of the patients, all five lobes were affected. The right lower lobe was most commonly involved (76%), and the right middle lobe (57%) was the least commonly affected [22].

In two other large studies with 138 and 99 confirmed cases, consolidative airspace opacities (referred to as “patchy shadows”) and GGO were the most commonly reported imaging features [23, 24]. Consistent with other studies, Pan et al. [6] reported patchy or punctate GGO in 85.7% and consolidative opacities in 19.0% of 63 patients. In their evaluation, approximately 70% of patients had multilobar involvement. Interstitial septal thickening (referred to as “enlarged fibrous stripes”) and pulmonary nodules were some of the less common findings. Jin et al. [4] described typical and atypical chest CT patterns. They reported bilateral, fuzzy-edged GGO with high density and small honeycomb interlobular septal thickening as typical findings in 54.2% of the patients, whereas multiple patchy consolidative opacities were also seen in 31.3% of the patients. In nearly 7% of the patients, they found atypical findings such as bronchial wall thickening, pleural effusions, lymphadenopathy, and pulmonary nodules surrounded by GGO.

CT Findings According to the Stage of the Disease

Jin et al. [4] described the characteristic CT findings of COVID-19 in five temporal stages as ultra-early, early, rapid progression, consolidation, and dissipation stages. During the ultra-early stage (asymptomatic, 1–2 weeks after exposure), CT may show single or multiple focal GGO, patchy consolidative opacities, pulmonary nodules encircled by GGO, and air bronchograms [4]. In the early stage (early symptomatic presentation, 54% of their cases), CT findings include single or multiple GGOs, or GGO combined with interlobu-

TABLE 1: Quality Ratings of Included Studies According to NIH Quality Assessment Tool for Case Series Studies

First Author [Reference No.]	Question ^a									Overall Rating	
	1	2	3	4	5	6	7	8	9	Reviewer 1	Reviewer 2
Huang [9]	Yes	Yes	NR	CD	NA	Yes	CD	Yes	Yes	Fair	Fair
Xie [8]	Yes	Yes	NR	CD	NA	Yes	CD	Yes	Yes	Fair	Fair
Song [19]	Yes	Yes	NR	CD	NA	Yes	CD	Yes	Yes	Fair	Fair
Chung [22]	Yes	Yes	Yes	CD	NA	Yes	CD	Yes	Yes	Fair	Fair
Wang [23]	Yes	Yes	NR	CD	NA	Yes	CD	Yes	Yes	Fair	Fair
Chen [24]	Yes	Yes	NR	CD	NA	Yes	CD	Yes	Yes	Fair	Fair
Fang [13]	Yes	Yes	NR	CD	NA	Yes	CD	NA	Yes	Fair	Fair
Lei [14]	Yes	Yes	NA	NA	NA	Yes	CD	NA	Yes	Fair	Fair
Shi [15]	Yes	Yes	NA	NA	NA	Yes	CD	NA	Yes	Fair	Fair
Chan [16]	Yes	Yes	NR	CD	NA	Yes	CD	NA	Yes	Fair	Fair
Jin [4]	Yes	No	NR	CD	NA	Yes	CD	Yes	Yes	Poor	Poor
Chang [32]	Yes	Yes	NR	CD	NA	Yes	CD	Yes	Yes	Fair	Fair
Kong [20]	Yes	Yes	NR	CD	NA	Yes	CD	NA	Yes	Fair	Fair
Li [21]	Yes	Yes	NA	NA	NA	Yes	CD	NA	Yes	Fair	Fair
Zhang [17]	Yes	Yes	NR	CD	NA	Yes	CD	NA	Yes	Fair	Fair
Kim [5]	Yes	Yes	NA	NA	NA	Yes	CD	NA	Yes	Fair	Fair
Pan [6]	Yes	Yes	NR	CD	NA	Yes	CD	Yes	Yes	Fair	Fair
Pan [25]	Yes	Yes	NR	CD	NA	Yes	CD	Yes	Yes	Fair	Fair
Xu [18]	Yes	Yes	NA	NA	NA	Yes	CD	NA	Yes	Fair	Fair
Huang [7]	Yes	Yes	NA	NA	NA	Yes	CD	NA	Yes	Fair	Fair
Diao [31]	Yes	Yes	CD	CD	NA	Yes	CD	Yes	Yes	Fair	Fair
Kui [33]	Yes	Yes	CD	CD	NA	Yes	CD	Yes	Yes	Fair	Fair
Chen [34]	Yes	Yes	CD	CD	NA	Yes	CD	NA	Yes	Fair	Fair
Wang [35]	Yes	Yes	CD	CD	NA	Yes	CD	NA	Yes	Fair	Fair
Kooraki [36]	Yes	Yes	CD	CD	NA	Yes	CD	NA	Yes	Fair	Fair
Duan [37]	Yes	Yes	NA	NA	NA	Yes	CD	Yes	Yes	Fair	Fair
Ng [38]	Yes	Yes	CD	CD	NA	Yes	CD	Yes	Yes	Fair	Fair
Yang ^b	Yes	Yes	CD	CD	NA	Yes	CD	Yes	Yes	Fair	Fair
Liu [39]	Yes	Yes	CD	CD	NA	Yes	CD	Yes	Yes	Fair	Fair
Yang ^c	Yes	Yes	CD	CD	NA	Yes	CD	Yes	Yes	Fair	Fair

Note—NIH = National Institutes of Health, NR = not reported, CD = cannot determine, NA = not applicable.

^aThe NIH Quality Assessment Tool for Case Series Studies [12] poses nine questions: 1 = Was the study question or objective clearly stated?, 2 = Was the study population clearly and fully described, including a case definition?, 3 = Were the cases consecutive?, 4 = Were the subjects comparable?, 5 = Was the intervention clearly described?, 6 = Were the outcome measures clearly defined, valid, reliable, and implemented consistently across all study participants?, 7 = Was the length of follow-up adequate?, 8 = Were the statistical methods well-described?, 9 = Were the results well-described? (Source: National Heart, Lung, and Blood Institute; National Institutes of Health; U.S. Department of Health and Human Services)

^bYang Z, et al., preliminary data.

^cYang W, et al., preliminary data.

lar septal thickening. In the rapid progression stage (days 3–7 of symptomatic presentation), CT findings include large, light consolidative opacities and air bronchograms [4]. During the consolidation stage (second week of symptomatic presentation), reductions in density and size of the consolidative opacities may be seen. About 2–3 weeks after the onset, CT may show dispersed patchy consolida-

tive opacities, reticular opacities (referred to as “strip-like opacities”), bronchial wall thickening, and interlobular septal thickening.

Song et al. [19] reported CT findings associated with disease progression, including an increased rate of consolidative opacities. Pan et al. [6] assessed the follow-up CT scans of 63 patients that were obtained within 3–14 days after an initial CT study. They

found that more than 85% of the patients showed imaging signs associated with disease progression such as increase in GGO, consolidative opacities, and interstitial septal thickening (referred to as “enlarged fibrous stripes”) [6]. In some patients with pulmonary nodules on initial CT, follow-up CT showed an increase in number and size or fusion of the nodules. However, they

Systematic Review of COVID-19 Imaging Findings

TABLE 2: Common Patterns and Distribution on Initial CT Images of 919 Patients With Coronavirus Disease (COVID-19)

Imaging Finding	No. of Studies	No. (%) of Reported Cases/ Total No. of Patients
Bilateral involvement	12	435/497 (87.5)
Peripheral distribution	12	92/121 (76.0)
Posterior involvement	1	41/51 (80.4)
Multilobar involvement	5	108/137 (78.8)
Ground-glass opacification	22	346/393 (88.0)
Consolidation	10	65/204 (31.8)

reported a decrease in the attenuation of some nodules over time [6].

In another study, Pan et al. [25] showed the temporal course of CT changes in 21 confirmed cases of COVID-19. In early stages, the majority of their patients showed more GGO and a lower number of involved lobes compared with the later follow-up scans. However, intensification of a crazy paving pattern, increase in the number of involved lobes, and appearance of consolidative opacities occurred in most patients over time. On average, CT findings were most prominent on day 10 of the disease. After day 14, improvement in imaging findings was reported in 75% of the patients, including decreased number of involved lobes and resolution of crazy paving pattern and consolidative opacities [25].

In other published studies, the most common findings on follow-up CT included increased consolidative opacities and loss of crazy paving pattern. Progression of GGO has been reported as an interval change in the early days after symptomatic presentation. Development of pleural effusions as well as progression to a mixed pattern of GGO and consolidative opacities have been reported in later disease stages [13–15].

CT Presentation According to Age Groups

Song et al. [19] reported GGO in 77% and consolidative opacities in 23% of patients younger than 50 years old. However, in patients older than 50 years old, GGO was reported in 55%, and consolidative opacities were present in 45% of the patients. The differences in rates of GGO and consolidative opacities were statistically significant between the age groups ($p < 0.001$). Atypical findings were also most commonly reported in older patients [4]. In a study on a family cluster, family members older than 60 years old showed more extensive GGO [16].

Relation Between RT-PCR Screening Result and Chest CT

CT findings and RT-PCR results were generally concordant in the included studies. However, there were six cases with remarkable CT findings despite an initial negative RT-PCR screening result. Huang et al. [7] reported a patient with suspected COVID-19 who presented with a 2-day history of flulike symptoms. Despite a negative RT-PCR result at the time of admission, CT showed bilateral peripheral GGO. A repeat CT performed on the 3rd day of admission showed evolution of GGO to consolidative opacities despite the RT-PCR screening test remaining negative until day 6. In another study with 167 patients, Xie et al. [8] reported five cases with initially negative real-time RT-PCR screening results who had typical CT findings of COVID-19 pneumonia. RT-PCR results became positive in all of these five patients after 2–8 days. In contrast, seven of the 167 patients did not show initial CT abnormalities despite an initial positive RT-PCR screening result. One of these patients developed imaging manifestations consistent with viral pneumonia within 5 days after the initial CT, and the fate of the other six was not reported. Similarly, Chung et al. [22] reported no GGO or consolidative opacities on initial imaging in three of 21 laboratory-confirmed patients, for whom a follow-up CT showed positive findings in two patients. The details of their confirmatory laboratory testing were not provided.

Discussion

In response to WHO's call for studies on the clinical characteristics of COVID-19, this systematic review was performed to identify the key imaging findings of COVID-19 and present the most recent evidence published in this early period of the outbreak for health care providers worldwide. With growing

global concerns about the COVID-19 outbreak, a comprehensive understanding of the diagnostic imaging hallmarks, atypical features, and evolution of chest imaging findings is essential for effective patient management and treatment.

The known imaging features of initial CT in COVID-19 cases include bilateral, multilobar GGO with a peripheral or posterior distribution (or both), mainly in the lower lobes and less frequently within the right middle lobe. Consolidation superimposed on GGO as the initial imaging presentation is found in a smaller number of cases, mainly in the elderly population. Septal thickening, bronchiectasis, pleural thickening, and subpleural involvement are some of the less common findings, mainly in the later stages of the disease. Pleural effusion, pericardial effusion, lymphadenopathy, cavitation, CT halo sign, and pneumothorax are some of the uncommon but possible findings seen with disease progression. Follow-up CT in the intermediate stages of the disease shows an increase in the number and size of GGOs, progressive transformation of GGO into multifocal consolidation, septal thickening, and development of a crazy paving pattern. The greatest severity of CT findings was visible around day 10 after symptom onset. ARDS is the most common indication for transferring patients with COVID-19 to the ICU and the major cause of ICU death in these patients. The imaging signs associated with clinical improvement usually occur after week 2 of the disease and include gradual resolution of consolidative opacities and decrease in the number of lesions and involved lobes. In the majority of documented COVID-19 cases, the initial chest CT is abnormal. Even some patients without any evident symptoms who were imaged solely on the basis of exposure have abnormal CT findings. Chest CT findings in confirmed cases of COVID-19 generally resembled those associated with MERS and severe acute respiratory syndrome (SARS), manifesting with viral pneumonia and acute lung injury that may progress to the typical imaging features of ARDS in critically ill patients [26–28]. According to our findings, chest CT showed similar characteristics in the majority of patients, including predominantly bilateral and multifocal involvement with a peripheral or posterior distribution (or both).

Different findings were reported during various stages of COVID-19 pneumo-

nia. However, there seemed to be a close relation between the pattern of CT findings and disease course. Several studies reported temporal changes in CT findings in follow-up examinations, including a transition from isolated GGO to a superimposition of consolidation on GGO with cavitation over time. Some studies suggested that CT manifestations of COVID-19 may vary across age groups, with a predominance of consolidative opacities in older patients and GGO in younger patients. However, there is a paucity of evidence on the long-term pulmonary effects of this infection [29]. Current studies are limited by their short follow-up periods, and CT findings in recovered patients have yet to be formally documented.

The correlation between CT findings and disease severity and mortality can be concluded from a number of studies. In severely ill patients, the most commonly reported CT findings were bilateral and multilobar involvement and subsegmental consolidative opacities. ARDS was the most common indication for transfer to the ICU, with the majority of COVID-19 mortalities occurring among patients with ARDS in the ICU.

Published clinical guidelines strongly recommend chest CT for patients with suspected COVID-19 [4]. RT-PCR screening is now considered the standard laboratory test for diagnosis of COVID-19, but it may yield a false-negative result in some cases. A number of cases with false-negative RT-PCR results were reported in the early stages of the disease, possibly because of inadequate viral material in the sample or technical issues during nucleic acid extraction [8, 30]. In such cases with typical clinical manifestations, chest CT may prove to be an invaluable asset because it may show characteristic features of the disease even when the RT-PCR screening test is negative [31].

A combination of chest CT and repeat laboratory testing may be beneficial for COVID-19 diagnosis in the setting of strong clinical suspicion, including individuals showing typical clinical manifestations and those with a history of exposure. However, a pretest probability assessment is necessary for accurate interpretation of diagnostic testing and application of these results in the appropriate clinical setting. More specifically, in a patient population with low pretest probability of SARS-CoV-2 infection, the typical imaging features should be interpreted with caution.

Study Limitations

A number of included studies were limited in terms of sample size, data availability, and methodologic quality. Therefore, the reported findings should be interpreted cautiously within that context. Furthermore, our study was limited to the articles published in English. Considering the epicenter of COVID-19, Chinese literature should be included in future systematic reviews. We will continue to monitor the literature, and this review will be updated when new evidence emerges.

Conclusion

This review of available English studies of COVID-19 provides insight into the initial and follow-up CT imaging findings for the disease.

Acknowledgments

We thank Fenxiang Song and Yuxin Shi of the Department of Radiology, Shanghai Public Health Clinical Center, Shanghai, China, for their valuable contributions to this article.

References

- World Health Organization website. Pneumonia of unknown cause: China. www.who.int/csr/don/05-january-2020-pneumonia-of-unknown-cause-china/en/. Accessed February 13, 2020
- World Health Organization website. Coronavirus disease (COVID-19) technical guidance: early investigations. www.who.int/emergencies/diseases/novel-coronavirus-2019/technical-guidance/early-investigations. Accessed February 15, 2020
- Johns Hopkins Whiting School of Engineering website. Coronavirus COVID-19 global cases. gisanddata.maps.arcgis.com/apps/opsdashboard/index.html#/bd7594740fd40299423467b48e9ecf6. Accessed February 20, 2020
- Jin YH, Cai L, Cheng ZS, et al.; Zhongnan Hospital of Wuhan University Novel Coronavirus Management and Research Team; Evidence-Based Medicine Chapter of China International Exchange and Promotive Association for Medical and Health Care (CPAM). A rapid advice guideline for the diagnosis and treatment of 2019 novel coronavirus (2019-nCoV) infected pneumonia (standard version). *Mil Med Res* 2020; 7:4
- Kim JY, Choe PG, Oh Y, et al. The first case of 2019 novel coronavirus pneumonia imported into Korea from Wuhan, China: implication for infection prevention and control measures. *J Korean Med Sci* 2020; 35:e61
- Pan Y, Guan H, Zhou S, et al. Initial CT findings and temporal changes in patients with the novel coronavirus pneumonia (2019-nCoV): a study of

- 63 patients in Wuhan, China. *Eur Radiol* 2020 Feb 13 [Epub ahead of print]
- Huang P, Liu T, Huang L, et al. Use of chest CT in combination with negative RT-PCR assay for the 2019 novel coronavirus but high clinical suspicion. *Radiology* 2020 Feb 12 [Epub ahead of print]
- Xie X, Zhong Z, Zhao W, Zheng C, Wang F, Liu J. Chest CT for typical 2019-nCoV pneumonia: relationship to negative RT-PCR testing. *Radiology* 2020 Feb 12 [Epub ahead of print]
- Huang C, Wang Y, Li X, et al. Clinical features of patients infected with 2019 novel coronavirus in Wuhan, China. *Lancet* 2020; 395:497–506
- World Health Organization website. WHO database of publications on coronavirus disease (COVID-2019). www.who.int/emergencies/diseases/novel-coronavirus-2019/global-research-on-novel-coronavirus-2019-ncov. Accessed February 19, 2020
- Moher D, Liberati A, Tetzlaff J, Altman DG; PRISMA Group. Preferred reporting items for systematic reviews and meta-analyses: the PRISMA statement. *PLoS Med* 2009; 6:e1000097
- National Heart, Lung, and Blood Institute website. Study quality assessment tools. www.nhlbi.nih.gov/health-topics/study-quality-assessment-tools. Accessed February 16, 2020
- Fang Y, Zhang H, Xu Y, Xie J, Pang P, Ji W. CT manifestations of two cases of 2019 novel coronavirus (2019-nCoV) pneumonia. *Radiology* 2020 Feb 7 [Epub ahead of print]
- Lei J, Li J, Li X, Qi X. CT imaging of the 2019 novel coronavirus (2019-nCoV) pneumonia. *Radiology* 2020 Jan 31 [Epub ahead of print]
- Shi H, Han X, Zheng C. Evolution of CT manifestations in a patient recovered from 2019 novel coronavirus (2019-nCoV) pneumonia in Wuhan, China. *Radiology* 2020 Feb 7 [Epub ahead of print]
- Chan JFW, Yuan S, Kok KH, et al. A familial cluster of pneumonia associated with the 2019 novel coronavirus indicating person-to-person transmission: a study of a family cluster. *Lancet* 2020; 395:514–523
- Zhang Z, Li X, Zhang W, Shi ZL, Zheng Z, Wang T. Clinical features and treatment of 2019-nCoV pneumonia patients in Wuhan: report of a couple cases. *Virol Sin* 2020 Feb 7 [Epub ahead of print]
- Xu X, Yu C, Zhang L, Luo L, Liu J. Imaging features of 2019 novel coronavirus pneumonia. *Eur J Nucl Med Mol Imaging* 2020 Feb 14 [Epub ahead of print]
- Song F, Shi N, Shan F, et al. Emerging coronavirus 2019-nCoV pneumonia. *Radiology* 2020 Feb 6 [Epub ahead of print]
- Kong W, Agarwal PP. Chest imaging appearance of COVID-19 infection. *Radiol Cardiothorac Imaging* 2020; 2:e200028

Systematic Review of COVID-19 Imaging Findings

21. Li X, Zeng X, Liu B, Yu Y. COVID-19 infection presenting with CT halo sign. *Radiol Cardiothorac Imaging* 2020; 2:e200026
22. Chung M, Bernheim A, Mei X, et al. CT imaging features of 2019 novel coronavirus (2019-nCoV). *Radiology* 2020 Feb 4 [Epub ahead of print]
23. Wang D, Hu B, Hu C, et al. Clinical characteristics of 138 hospitalized patients with 2019 novel coronavirus-infected pneumonia in Wuhan, China. *JAMA* 2020 Feb 7 [Epub ahead of print]
24. Chen N, Zhou M, Dong X, et al. Epidemiological and clinical characteristics of 99 cases of 2019 novel coronavirus pneumonia in Wuhan, China: a descriptive study. *Lancet* 2020; 395:507–513
25. Pan F, Ye T, Sun P, et al. Time course of lung changes on chest CT during recovery from 2019 novel coronavirus (COVID-19) pneumonia. *Radiology* 2020 Feb 13 [Epub ahead of print]
26. Das KM, Lee EY, Al Jawder SE, et al. Acute Middle East respiratory syndrome coronavirus: temporal lung changes observed on the chest radiographs of 55 patients. *AJR* 2015; 205:[web] W267–W274
27. Müller NL, Ooi GC, Khong PL, Zhou LJ, Tsang KWT, Nicolaou S. High-resolution CT findings of severe acute respiratory syndrome at presentation and after admission. *AJR* 2004; 182:39–44
28. Ooi GC, Khong PL, Müller NL, et al. Severe acute respiratory syndrome: temporal lung changes at thin-section CT in 30 patients. *Radiology* 2004; 230:836–844
29. Kanne JP. Chest CT findings in 2019 novel coronavirus (2019-nCoV) infections from Wuhan, China: key points for the radiologist. *Radiology* 2020 Feb 4 [Epub ahead of print]
30. Corman VM, Landt O, Kaiser M, et al. Detection of 2019 novel coronavirus (2019-nCoV) by real-time RT-PCR. *Euro Surveill* 2020 Jan 25 [Epub ahead of print]
31. Diao K, Han P, Pang T, Li Y, Yang Z. HRCT imaging features in representative imported cases of 2019 novel coronavirus pneumonia. *Precis Clin Med* 2020 Feb 11 [Epub ahead of print]
32. Chang D, Lin M, Wei L, et al. Epidemiologic and clinical characteristics of novel coronavirus infections involving 13 patients outside Wuhan, China. *JAMA* 2020 Feb 7 [Epub ahead of print]
33. Kiu K, Fang YY, Deng Y, et al. Clinical characteristics of novel coronavirus cases in tertiary hospitals in Hubei Province. *Chin Med J (Engl)* 2020 Feb 7 [Epub ahead of print]
34. Chen H, Guo J, Wang C, et al. Clinical characteristics and intrauterine vertical transmission potential of COVID-19 infection in nine pregnant women: a retrospective review of medical records. *Lancet* 2020 Feb 12 [Epub ahead of print]
35. Wang Z, Chen X, Lu Y, Chen F, Zhang W. Clinical characteristics and therapeutic procedure for four cases with 2019 novel coronavirus pneumonia receiving combined Chinese and Western medicine treatment. *Biosci Trends* 2020 Feb 9 [Epub ahead of print]
36. Kooraki S, Hosseiny M, Myers L, Gholamrezazadeh A. Coronavirus outbreak: what the department of radiology should know. *J Am Coll Radiol* 2020 Feb 19 [Epub ahead of print]
37. Duan YN, Qin J. Pre- and posttreatment chest CT findings: 2019 novel coronavirus (2019-nCoV) pneumonia. *Radiology* 2020 Feb 12 [Epub ahead of print]
38. Ng MY, Lee EY, Yang J, et al. Imaging profile of the COVID-19 infection: radiologic findings and literature review. *Radiol Cardiothorac Imaging* 2020; 2:e200034
39. Liu Y, Yang Y, Zhang C, et al. Clinical and biochemical indexes from 2019-nCoV infected patients linked to viral loads and lung injury. *Sci China Life Sci* 2020; 63:364–374

FOR YOUR INFORMATION

A data supplement for this article can be viewed in the online version of the article at: www.ajronline.org.