

CT Features of Coronavirus Disease 2019 (COVID-19) Pneumonia in 62 Patients in Wuhan, China

Shuchang Zhou¹
Yujin Wang
Tingting Zhu
Liming Xia

OBJECTIVE. The purpose of this study was to investigate 62 subjects in Wuhan, China, with laboratory-confirmed coronavirus disease (COVID-19) pneumonia and describe the CT features of this epidemic disease.

MATERIALS AND METHODS. A retrospective study of 62 consecutive patients with laboratory-confirmed COVID-19 pneumonia was performed. CT images and clinical data were reviewed. Two thoracic radiologists evaluated the distribution and CT signs of the lesions and also scored the extent of involvement of the CT signs. The Mann-Whitney *U* test was used to compare lesion distribution and CT scores. The chi-square test was used to compare the CT signs of early-phase versus advanced-phase COVID-19 pneumonia.

RESULTS. A total of 62 patients (39 men and 23 women; mean [\pm SD] age, 52.8 ± 12.2 years; range, 30–77 years) with COVID-19 pneumonia were evaluated. Twenty-four of 30 patients who underwent routine blood tests (80.0%) had a decreased lymphocyte count. Of 27 patients who had their erythrocyte sedimentation rate and high-sensitivity C-reactive protein level assessed, 18 (66.7%) had an increased erythrocyte sedimentation rate, and all 27 (100.0%) had an elevated high-sensitivity C-reactive protein level. Multiple lesions were seen on the initial CT scan of 52 of 62 patients (83.9%). Forty-eight of 62 patients (77.4%) had predominantly peripheral distribution of lesions. The mean CT score for the upper zone (3.0 ± 3.4) was significantly lower than that for the middle (4.5 ± 3.8) and lower (4.5 ± 3.7) zones ($p = 0.022$ and $p = 0.020$, respectively), and there was no significant difference in the mean CT score of the middle and lower zones ($p = 1.00$). The mean CT score for the anterior area (4.4 ± 4.1) was significantly lower than that for the posterior area (7.7 ± 6.3) ($p = 0.003$). CT findings for the patients were as follows: 25 patients (40.3%) had ground-glass opacities (GGO), 21 (33.9%), consolidation; 39 (62.9%), GGO plus a reticular pattern; 34 (54.8%), vacuolar sign; 28 (45.2%), microvascular dilation sign; 35 (56.5%), fibrotic streaks; 21 (33.9%), a subpleural line; and 33 (53.2%), a subpleural transparent line. With regard to bronchial changes seen on CT, 45 patients (72.6%) had air bronchogram, and 11 (17.7%) had bronchus distortion. In terms of pleural changes, CT showed that 30 patients (48.4%) had pleural thickening, 35 (56.5%) had pleural retraction sign, and six (9.7%) had pleural effusion. Compared with early-phase disease (≤ 7 days after the onset of symptoms), advanced-phase disease (8–14 days after the onset of symptoms) was characterized by significantly increased frequencies of GGO plus a reticular pattern, vacuolar sign, fibrotic streaks, a subpleural line, a subpleural transparent line, air bronchogram, bronchus distortion, and pleural effusion; however, GGO significantly decreased in advanced-phase disease.

CONCLUSION. CT examination of patients with COVID-19 pneumonia showed a mixed and diverse pattern with both lung parenchyma and the interstitium involved. Identification of GGO and a single lesion on the initial CT scan suggested early-phase disease. CT signs of aggravation and repair coexisted in advanced-phase disease. Lesions presented with a characteristic multifocal distribution in the middle and lower lung regions and in the posterior lung area. A decreased lymphocyte count and an increased high-sensitivity C-reactive protein level were the most common laboratory findings.

Keywords: coronavirus disease 2019, COVID-19, CT, pneumonia

doi.org/10.2214/AJR.20.22975

Received February 16, 2020; accepted without revision February 19, 2020.

¹All authors: Department of Radiology, Tongji Hospital, Tongji Medical College, Huazhong University of Science and Technology, 1095 Jiefang Rd, Qiaokou District, Wuhan, Hubei 430030, China. Address correspondence to Y. Wang (wangyujin8303@163.com).

AJR 2020; 215:1–8

ISSN-L 0361–803X/20/2154–1

© American Roentgen Ray Society

Since late December of 2019, an explosion in the number of cases of a new acute viral respiratory disease (coronavirus disease [COVID-19]) caused by a novel coronavirus (severe acute respiratory syndrome coronavirus 2 [SARS-CoV-2]) has been reported in the city of Wuhan in central China. Accord-

ing to the initial investigation, most cases were thought to originate from the Huanan Seafood Wholesale Market in Wuhan [1]. At the time of the writing of this article, the virus is rapidly spreading to many other cities in China and even to other countries around the world. Although SARS-CoV-2 is a member of the coronavirus family of viruses, it is

more distant from SARS coronavirus (SARS-CoV) and Middle East respiratory syndrome coronavirus, is considered to be a new type of betacoronavirus that infects humans [2], and on the basis of the current epidemic, is more infectious than SARS-CoV. As of 8:00 p.m. on February 17, 2020, a total of 68,595 confirmed cases of COVID-19 and 1667 deaths were reported. In the present study, we identified 62 patients in Wuhan, China, who had laboratory-confirmed COVID-19 pneumonia and described the CT features of this pneumonia.

Materials and Methods

The ethics committee at Huazhong University of Science and Technology waived the need for informed consent for this retrospective study.

We retrospectively reviewed 118 patients seen with suspected COVID-19 pneumonia from January 16 to January 30, 2020. All patients had abnormal CT findings that suggested pneumonia as the diagnosis. A patient with suspected COVID-19 pneumonia was defined as a patient with pneumonia who met at least three of the following five criteria: fever, a low or normal WBC count or low lymphocyte count, exclusion of other respiratory virus species on the basis of laboratory findings, no relief in symptoms noted after receipt of empirical antimicrobial or antiinfluenza treatment for 3 days, and in particular, an epidemiologic link to the Huanan Seafood Wholesale Market or a history of contact with other patients with COVID-19 pneumonia. A total of 62 patients were confirmed to have COVID-19 nucleic acid on the basis of positive findings for respiratory samples tested using real-time reverse-transcription-polymerase chain reaction. Two of the researchers recorded clinical data, including symptoms, date of onset of symptoms, laboratory examination results, and information regarding other accompanying conditions or diseases.

CT Scanning Protocol

MDCT was performed using either of the following CT scanners: the 16-MDCT LightSpeed scanner (GE Healthcare) or the uCT 760 scanner (United Imaging). The parameters used for the scanning protocol were as follows: patient in the supine position; end inspiratory acquisition; tube voltage, 100–120 kV; tube current–exposure time product, 200–300 mAs; pitch, 1.375 and 0.9125; and section thickness after reconstruction, 1.25 mm. Unenhanced CT scans were obtained for all patients.

Image Viewing and Evaluation

Two experienced radiologists with 13 and 39 years of experience in thoracic radiology retro-

spectively reviewed the CT images on a PACS workstation (Synapses, Fujifilm) with multiplanar reconstruction tools and reached a decision in consensus. The images were viewed in lung window settings (width, 1000–1500 HU; level, 700 to –550 HU) and mediastinal window settings (width, 300–350 HU; level, 30–40 HU). The predominant patterns seen on CT images were classified into three major categories: lung, bronchial, and pleural changes. Each major category was divided into subcategories. Lung changes were classified into the following eight subcategories: ground-glass opacities (GGO; increased attenuation without obscuration of the underlying lung vessels) [3], consolidation (homogeneous increased intensity of lung parenchyma with obscuration of the underlying vessels), GGO plus a reticular pattern (a reticular shadow on the background of GGO and thickening of the interlobular septum and interlobular septum, showing paving stone sign) [4], vacuolar sign (a vacuole-like transparent shadow of < 5 mm in length observed in the lesion), microvascular dilation sign (dilated small vessels in the lesion), fibrotic streaks (an irregular strip shadow), a subpleural line (an arc-shaped linear shadow 2–5 cm in length appearing parallel to the chest wall), or a subpleural transparent line (a thin and transparent line lying between the lesions and the visceral layer of pleura). Bronchial changes were classified into two subcategories: air bronchogram (an air-filled image of bronchus in lung lesions) and bronchus distortion. Pleural changes were classified into three subcategories: thickening of the pleura, pleural retraction sign (lesions present close to the visceral pleura and pull pleura), or pleural effusion. Distribution of the lung lesions was classified as predominantly peripheral (involving mainly the peripheral region comprising one-third of the lung), central (involving mainly the central region comprising two-thirds of the lung), or peripheral plus central (involving both the peripheral and central regions) [5]. Because no cases of lymphadenopathy and pneumothorax were found, those two signs will not be described in the present study.

The extent of involvement on thin-section CT images was also assessed by the two radiologists. Each side of the lung was divided (from top to bottom) into three zones: the upper zone (above the carina), the middle zone (from the carina to the inferior pulmonary vein), and the lower zone (below the inferior pulmonary vein). Each zone was then divided into two areas: the anterior area (the area before the vertical line of the midpoint of the diaphragm in the sagittal position) and the posterior area (the area after the vertical line of the midpoint of the diaphragm in the sagittal position). Fi-

nally, bilateral lungs were divided into 12 zones altogether. The degree of involvement in each lung zone was scored as follows [6–8]: a score of 0 denoted no involvement; 1, < 25% involvement; 2, 25% to less than 50% involvement; 3, 50% to less than 75% involvement; and 4, ≥ 75% involvement. Scores were recorded and summed for each lung zone, with a maximum possible score of 48.

Statistical Analysis

Data were recorded using spreadsheet software (Excel 2010, Microsoft) and were analyzed using statistical software (SPSS, version 22.0, IBM). Continuous variables were expressed as mean (\pm SD) values. The Kolmogorov-Smirnov test was used for the normal distribution test, and continuous variables were compared using the Mann-Whitney *U* test. The frequency of CT signs was expressed as the number (percentage) of occurrences and was compared for cases of early- versus advanced-phase disease using the chi-square test or the Fisher exact test. Differences for which $p < 0.05$ were considered statistically significant.

Results

Clinical Characteristics

A total of 62 patients (mean age, 52.8 \pm 12.2 years; range, 30–77 years) with COVID-19 pneumonia were included in the study. Thirty-nine of the 62 patients (62.9%) were men (mean age, 54.1 \pm 11.8 years; range, 30–77 years), and 23 (37.1%) were women (mean age, 50.7 \pm 12.8 years; range, 30–73 years). All patients had symptoms at onset of the disease, with fever noted in 54 patients (87.1%), coughing and sputum in 28 patients (45.2%), fatigue in 14 patients (22.6%), shortness of breath in 15 patients (24.2%), muscle pain in 20 patients (32.3%), and gastrointestinal symptoms, including abdominal pain and diarrhea, in nine patients (14.5%). Routine blood tests were performed for 30 patients. Six patients (20.0%) had leukopenia, 24 (80.0%) had a decreased lymphocyte count, and 15 (50.0%) had a decreased percentage of lymphocytes. The erythrocyte sedimentation rate and high-sensitivity C-reactive protein (hs-CRP) level were evaluated in 27 patients. Of these patients, 18 (66.7%) had an increased erythrocyte sedimentation rate, and all 27 (100.0%) had an elevated hs-CRP level. Four patients had a history of hypertension, four had diabetes, one had cerebral infarction, one had chronic kidney disease, and two were pregnant. Table 1 summarizes the demographic and clinical characteristics of the patients.

CT Features of COVID-19 Pneumonia

TABLE 1: Demographic and Clinical Characteristics of Patients With Coronavirus Disease 2019 Pneumonia

Characteristic	Value
Sex, no. of patients/total patients	
Male	39/62
Female	23/62
Symptom, no. of patients/total patients	
Fever	54/62
Coughing and sputum	28/62
Fatigue	14/62
Shortness of breath	15/62
Muscle pain	20/62
Abdominal pain or diarrhea	9/62
Laboratory test finding, no. of patients/total patients	
Leukopenia	6/30
Decreased lymphocyte count	24/30
Decreased percentage of lymphocytes	15/30
Increased ESR	18/27
Increased hs-CRP level	27/27
Accompanying condition or disease, no. of patients	
Hypertension	4
Diabetes	4
Cerebral infarction	1
Chronic kidney disease	1
Pregnancy	2

Note—ESR = erythrocyte sedimentation rate, hs-CRP = high-sensitivity C-reactive protein.

CT Findings of Coronavirus Disease 2019 Pneumonia

In 10 of 62 patients (16.1%), COVID-19 pneumonia was seen as a single lesion on the first CT scan obtained, with CT performed 1–7 days (mean, 2.2 ± 1.8 days) after the onset of symptoms. In the remaining 52 patients (83.9%), COVID-19 pneumonia was seen as multiple lesions on the first CT scan obtained, with CT performed 1–14 days (mean, 6.6 ± 4.0 days) after the onset of symptoms, a significantly longer interval than that noted for patients with a single lesion ($p < 0.05$). Of the 10 patients with a single lesion, seven (70.0%) had lesions that were initially located in the inferior lobe of the right lung; of the three remaining patients in this group, one (10.0%) had a lesion located in the middle lobe of the right lung, one (10.0%) had a lesion in the upper lobe of the right lung, and

TABLE 2: Distribution and CT Score for Parenchymal Abnormalities in 62 Patients With Coronavirus Disease 2019 Pneumonia

Category and Subcategory	No. (%) of Patients	CT Score, Mean \pm SD	<i>p</i>
Lesion distribution			0.008 ^a
Peripheral	48 (77.4)		
Peripheral and central	14 (22.6)		
Lung			0.750
Left		5.9 ± 5.1	
Right		6.2 ± 5.3	
Lung zone			0.024 ^a
Upper		3.0 ± 3.4	
Middle		4.5 ± 3.8	
Lower		4.5 ± 3.7	
Lung area			0.003 ^a
Anterior		4.4 ± 4.1	
Posterior		7.7 ± 6.3	

^aStatistically significant difference.

one (10.0%) had a lesion in the lingual segment of the upper lobe of the left lung.

In terms of lesion distribution, distribution was predominantly peripheral in 48 of 62 patients (77.4%), peripheral plus central in 14 patients (22.6%) cases, and central in none of the patients. When the CT score was used to determine the extent of involvement, we compared involvement of the left and right lungs; the upper, middle, and lower zones; and the anterior and posterior areas. No significant difference was observed between the mean CT scores for the left lung (5.9 ± 5.1) and right lung (6.2 ± 5.3) ($p = 0.75$). The mean CT score for the upper zone (3.0 ± 3.4) was significantly lower than that for the middle (4.5 ± 3.8) and lower (4.5 ± 3.7) zones ($p = 0.022$ and $p = 0.020$, respectively), and no significant difference was observed between those of the middle and lower zones ($p = 1.00$). The mean CT score for the anterior area (4.4 ± 4.1) was significantly lower than that for the posterior area (7.7 ± 6.3) ($p = 0.003$) (Fig. 1 and Table 2).

The CT features of COVID-19 pneumonia included lung changes (GGO, consolidation, GGO plus a reticular pattern, vacuolar sign, microvascular dilation sign, fibrotic streaks, a subpleural line, and a subpleural transparent line), bronchial changes (air bronchogram and bronchus distortion) and pleural changes (pleural thickening, pleural retraction sign, and pleural effusion). In terms of lung changes, CT showed that 25 patients (40.3%) had GGO and 21 (33.9%) had consolidation; these findings are somewhat sim-

ilar to those of a previous study [8]. Other lung changes that were observed on CT were as follows: 39 patients (62.9%) had GGO plus a reticular pattern; 34 (54.8%), vacuolar sign; 28 (45.2%), microvascular dilation sign; 35 (56.5%), fibrotic streaks; 21 (33.9%), a subpleural line; and 33 (53.2%), a subpleural transparent line. In terms of bronchial changes, 45 patients (72.6%) had air bronchogram on CT, and 11 (17.7%) had bronchus distortion. With regard to pleural changes seen on CT, 30 patients (48.4%) had thickening of pleura, 35 (56.5%) had pleural retraction sign, and six (9.7%) had pleural effusion (Table 2 and Figs. 2–4).

When the course of disease was divided into an early phase (≤ 7 days after the onset of symptoms) ($n = 40$) and an advanced phase (8–14 days after the onset of symptoms) ($n = 22$), we found that the frequency of GGO was significantly higher in early-phase disease than in advanced-phase disease. The frequencies of GGO plus a reticular pattern, vacuolar sign, fibrotic streaks, a subpleural line, a subpleural transparent line, air bronchogram, bronchus distortion, and pleural effusion were also significantly lower in patients with early-phase disease compared with those with advanced-phase disease (Tables 3 and 4).

Discussion

COVID-19 pneumonia is a new, highly contagious viral pneumonia caused by a novel coronavirus (SARS-CoV-2) of unclear origin. In this study, we investigated 62 patients

TABLE 3: CT Features of Coronavirus Disease 2019 Pneumonia

CT Feature	No. (%) of Patients (n = 62)
Lesion presentation on initial scan	
Single lesion	10 (16.1)
Multiple lesions	52 (83.9)
Lesion distribution	
Peripheral	48 (77.4)
Peripheral and central	14 (22.6)
CT sign	
Lung change	
GGO	25 (40.3)
Consolidation	21 (33.9)
GGO and reticular pattern	39 (62.9)
Vacuolar sign	34 (54.8)
Microvascular dilation sign	28 (45.2)
Fibrotic streaks	35 (56.5)
Subpleural line	21 (33.9)
Subpleural transparent line	33 (53.2)
Bronchial change	
Air bronchogram	45 (72.6)
Bronchiectasis	20 (32.2)
Bronchus distortion	11 (17.7)
Pleural change	
Thickening of pleura	30 (48.4)
Pleural retraction sign	35 (56.5)
Pleural effusion	6 (9.7)

Note—GGO = ground-glass opacities.

with confirmed COVID-19 pneumonia. Most (62.9%) of the infected patients were men. In terms of symptoms, fever occurred in 87.1% of patients; coughing and sputum, in 45.2%; muscle pain, 32.3%; shortness of breath, 24.2%; fatigue, 22.6%; and gastrointestinal symptoms such as abdominal pain and diarrhea, 14.5%. In addition to respiratory and systemic symptoms of viral infection, some patients with COVID-19 pneumonia presented with a gastrointestinal symptom as the initial symptom; this finding suggests that gastrointestinal symptoms may be associated with the pathogenesis of COVID-19 pneumonia as a result of the virus binding to human receptor angiotensin-converting enzyme 2 [9], which also shows high expression in the gastrointestinal tract [10]. In terms of laboratory findings, 80.0% of patients had a decreased lymphocyte count [11], and 50.0% of

TABLE 4: CT Features of Coronavirus Disease 2019 Pneumonia in Patients With Early- and Advanced-Phase Disease

CT Feature	Early-Phase Disease (n = 40)	Advanced-Phase Disease (n = 22)	Chi-Square Test Statistic	p
Lung change				
GGO	19 (47.5)	6 (27.3)	2.413	0.012 ^a
Consolidation	15 (37.5)	6 (27.3)	0.663	0.416
GGO and reticular pattern	20 (50.0)	19 (86.4)	8.043	0.005 ^a
Vacuolar sign	16 (40.0)	18 (81.8)	10.022	0.002 ^a
Microvascular dilation sign	19 (47.5)	9 (40.9)	0.249	0.618
Fibrotic streaks	17 (42.5)	18 (81.8)	8.925	0.003 ^a
Subpleural line	10 (25.0)	11 (50.0)	3.961	0.047 ^a
Subpleural transparent line	17 (42.5)	16 (72.7)	5.209	0.022 ^a
Bronchial change				
Air bronchogram	25 (62.5)	20 (90.9)	5.756	0.016 ^a
Bronchus distortion	4 (10.0)	7 (31.8)	4.630	0.031 ^a
Pleural change				
Thickening of pleura	17 (42.5)	13 (59.1)	1.564	0.211
Pleural retraction sign	23 (57.5)	12 (54.5)	0.050	0.822
Pleural effusion	1 (2.5)	5 (22.7)	6.644	0.010 ^a

Note—Except where otherwise indicated, data are number (%) of patients. All comparisons were performed using the chi-square test. GGO = ground-glass opacities.

^aStatistically significant difference.

patients had a decreased percentage of lymphocytes. Of 27 patients who underwent evaluation of the erythrocyte sedimentation rate and hs-CRP level, 66.7% had an increased erythrocyte sedimentation rate, and 100.0% had an elevated hs-CRP level. Therefore, a decreased lymphocyte count and an elevated hs-CRP level were the most sensitive parameters.

In reviewing and analyzing the CT features of 62 cases of COVID-19 pneumonia, we found that cases were most often seen to manifest as multiple lesions on the initial CT scan (83.9%); however, 16.1% of cases manifested as single lesion, and of these cases, 70.0% occurred in the inferior lobe of the right lung. When patients with single and multiple lesions were compared, multiple lesions were identified on imaging performed at a mean of 6.6 ± 4.0 days after onset of symptoms, whereas single lesions were identified on imaging performed at a significantly earlier phase of the disease (2.2 ± 1.8 days). This may be because of the innate anatomic features of the right inferior lobar bronchus. The bronchus of the right lower lobe of the lung is straighter and steeper than other bronchial branches, and the angle between the right lower lobe and the long axis of the trachea is smaller, so in the early phase of the disease, the virus is more likely

to invade the branches of the right inferior lobar bronchus and cause infection. Considering the range of involvement, we found that lesions showed a predominantly peripheral distribution (75.8%). The middle and lower zones and the posterior area of both lungs were significantly more involved.

We found diversified CT patterns of COVID-19 pneumonia, including lung changes (GGO [40.3%], consolidation [33.9%], GGO plus a reticular pattern [62.9%], vacuolar sign [54.8%], microvascular dilation sign [45.2%], fibrotic streaks [56.5%], subpleural line [33.9%], subpleural transparent line [53.2%]), bronchial changes (air bronchogram [72.6%] and bronchus distortion [17.7%]), and pleural changes (thickening of pleura [48.4%], pleural retraction sign [56.5%], and pleural effusion [9.7%]). On CT, the COVID-19 pneumonia was seen to have a rather mixed pattern involving both lung parenchyma and lung interstitium [12]. The virus first invaded the pulmonary interstitium, which was characterized by edema and thickening of the interlobular septum, interlobular interstitium, subpleural interstitium, interlobular central interstitium, and peribronchovascular interstitium, manifesting as GGO. Consolidation might represent further infiltration of the parenchyma. The vacuole sign could be caused

CT Features of COVID-19 Pneumonia

by an incompletely filled alveolar cluster in the exudative lung parenchyma. The microvascular dilation sign probably indicated increased blood supply to the inflammatory area. Air bronchogram was formed by bronchus containing air in consolidation. GGO plus a reticular pattern represented thickening of the interlobular septum resulting from the GGO, which ultimately evolved into the subpleural line. Fibrotic streaks indicated local inflammatory absorption and residual fibrosis, and bronchus distortion suggested that the local inflammation absorbed and retracted the bronchus inside or surrounded it. The pleura were often involved and were characterized by thickening and retraction resulting from the inflammatory reaction.

In early-phase COVID-19 pneumonia (≤ 7 days after the onset of symptoms), bronchus distortion (10.0%) and pleural effusion (2.5%) were relatively rare compared with other signs (frequency, 27.5–62.5%). In advanced-phase disease (8–14 days after the onset of symptoms), GGO plus a reticular pattern (86.4%), vacuolar sign (81.8%), air bronchogram (81.8%), fibrotic streaks (90.9%), and the subpleural transparent line (72.7%) were relatively more common than other signs (frequency, 22.7–59.1%). Compared with early-phase disease, advanced-phase disease was associated with a significantly increased frequency of GGO plus a reticular pattern, vacuolar sign, fibrotic streaks, air bronchogram, bronchus distortion, a subpleural line, a subpleural transparent line, and pleural effusion, but GGO was significantly decreased. These changes suggested that GGO was a relatively early sign in the course of the disease and that in the advanced phase, the involvement of lung parenchyma and interstitium was aggravated but

was accompanied by repair changes. There was no significant difference between early-phase disease versus advanced-phase disease in terms of consolidation, the microvascular dilation sign, thickening of pleura, and the pleural retraction sign.

The present study has two limitations. First, because the course of COVID-19 pneumonia is short, changes seen on CT over its entire course have not been completely tracked and described for all patients. Second, there is not enough pathologic data on these patients for a comparative study to be performed.

In conclusion, CT findings for patients with COVID-19 pneumonia showed that the disease has a mixed and diverse pattern, with both lung parenchyma and interstitium involved. The presence of GGO and a single lesion at the onset of COVID-19 pneumonia suggested that the disease was in its early phase. CT signs of aggravation and repair coexisted in examinations of patients with advanced-phase disease. Pleural effusion might occur in the advanced phase. Multifocality as well as primary distribution of lesions in the middle and lower zones and the posterior area of the lungs were rather characteristic manifestations. A decreased lymphocyte count and an elevated hs-CRP level were the most common laboratory findings.

Acknowledgment

We thank Zujun Hou for assistance in revising this manuscript.

References

1. Huang C, Wang Y, Li X, et al. Clinical features of patients infected with 2019 novel coronavirus in Wuhan, China. *Lancet* 2020; 395:497–506 [Erratum in *Lancet* 2020; 395:496].
2. Lu R, Zhao X, Li J, et al. Genomic characterisation and epidemiology of 2019 novel coronavirus: implications for virus origins and receptor binding. *Lancet* 2020; 395:565–574

3. Joynt GM, Antonio GE, Lam P, et al. Late-stage adult respiratory distress syndrome caused by severe acute respiratory syndrome: abnormal findings at thin-section CT. *Radiology* 2004; 230:339–346
4. Wong KT, Antonio GE, Hui DS, et al. Thin-section CT of severe acute respiratory syndrome: evaluation of 73 patients exposed to or with the disease. *Radiology* 2003; 228:395–400
5. Ajlan AM, Ahyad RA, Jamjoom LG, Alharthy A, Madani TA. Middle East respiratory syndrome coronavirus (MERS-CoV) infection: chest CT findings. *AJR* 2014; 203:782–787
6. Ooi GC, Khong PL, Müller NL, et al. Severe acute respiratory syndrome: temporal lung changes at thin-section CT in 30 patients. *Radiology* 2004; 230:836–844
7. Chang YC, Yu CJ, Chang SC, et al. Pulmonary sequelae in convalescent patients after severe acute respiratory syndrome: evaluation with thin-section CT. *Radiology* 2005; 236:1067–1075
8. Chung M, Bernheim A, Mei X, et al. CT imaging features of 2019 novel coronavirus (2019-nCoV). *Radiology* 2020 Feb 24 [Epub ahead of print]
9. Wan Y, Shang J, Graham R, Baric RS, Li F. Receptor recognition by novel coronavirus from Wuhan: an analysis based on decade-long structural studies of SARS. *J Virol* 2020 Jan 29 [Epub ahead of print]
10. Harmer D, Gilbert M, Borman R, Clark KL. Quantitative mRNA expression profiling of ACE 2, a novel homologue of angiotensin converting enzyme. *FEBS Lett* 2002; 532:107–110
11. Chen N, Zhou M, Dong X, et al. Epidemiological and clinical characteristics of 99 cases of 2019 novel coronavirus pneumonia in Wuhan, China: a descriptive study. *Lancet* 2020; 395:507–513
12. Koo HJ, Lim S, Choe J, Choi SH, Sung H, Do KH. Radiographic and CT features of viral pneumonia. *RadioGraphics* 2018; 38:719–739

(Figures start on next page)

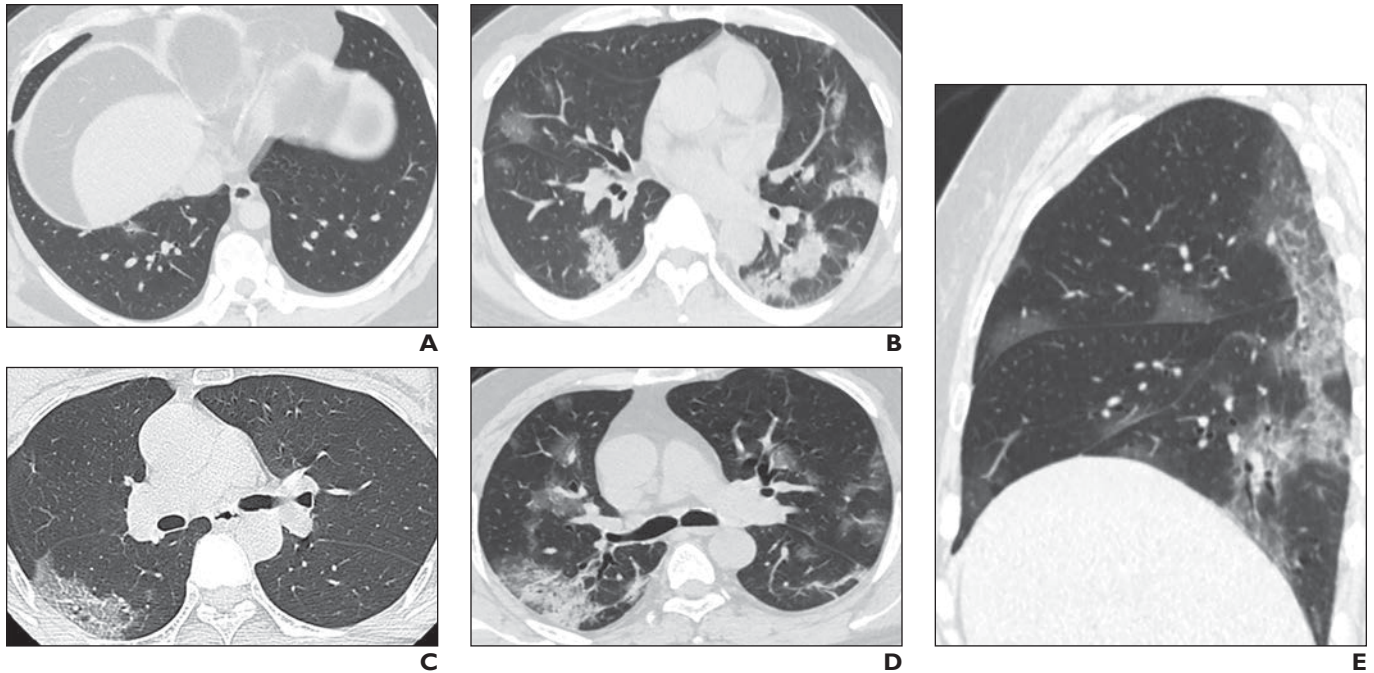


Fig. 1—Distribution of lesions in five patients with coronavirus disease 2019 pneumonia.
A, 30-year-old man. CT image obtained on day 2 after onset of symptoms shows single lesion that developed in inferior lobe of right lung.
B, 49-year-old man. CT image obtained on day 7 after onset of symptoms shows multiple lesions involving multiple lobes of bilateral lungs.
C, 38-year-old man. CT image obtained on day 5 after onset of symptoms shows peripheral distribution of patchy ground-glass opacities plus reticular pattern with vacuole inside.
D, 46-year-old woman. CT image obtained on day 9 after onset of symptoms shows peripheral plus central distribution of ground-glass opacities, partial consolidation, and fibrosis streak.
E, 38-year-old woman. CT image obtained on day 7 after onset of symptoms shows posterior area with more serious involvement than anterior area.

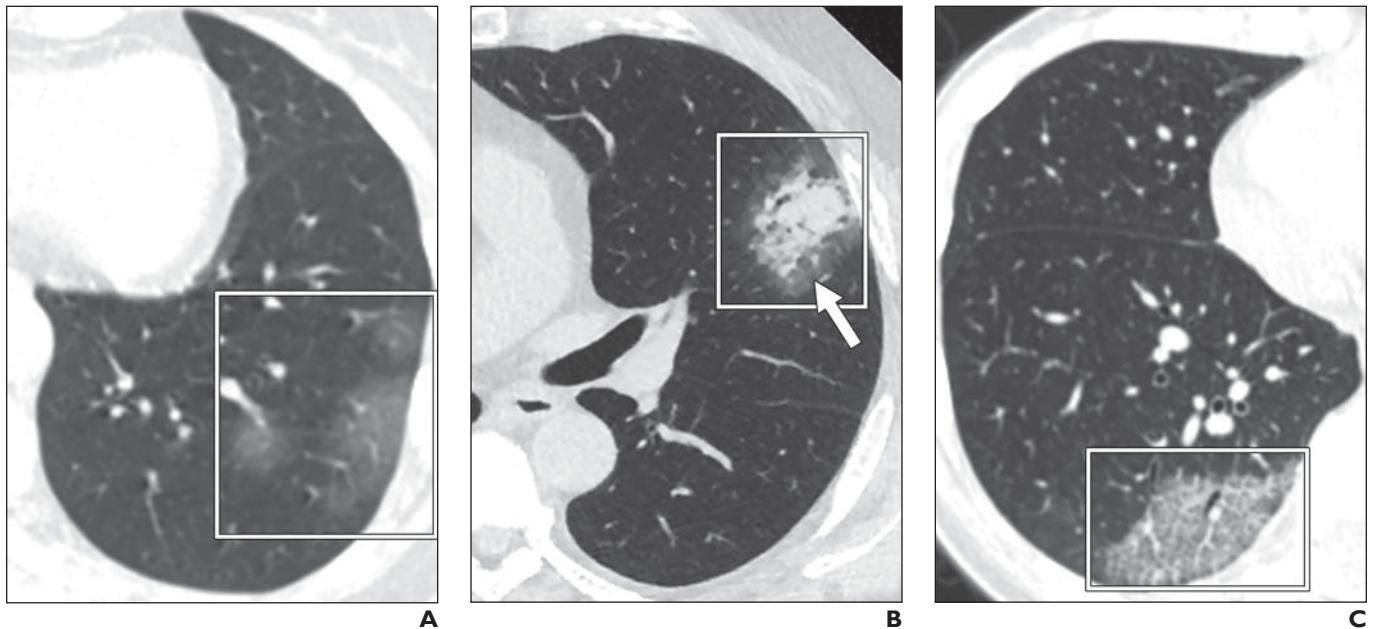
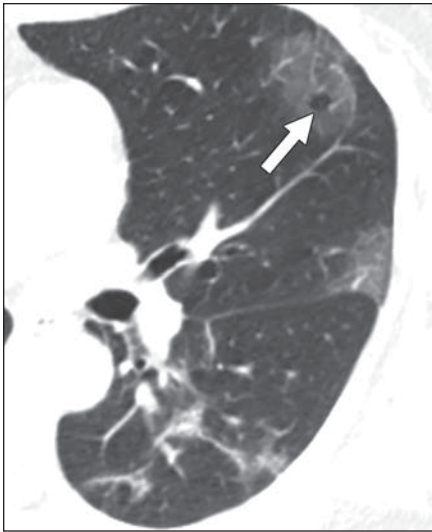


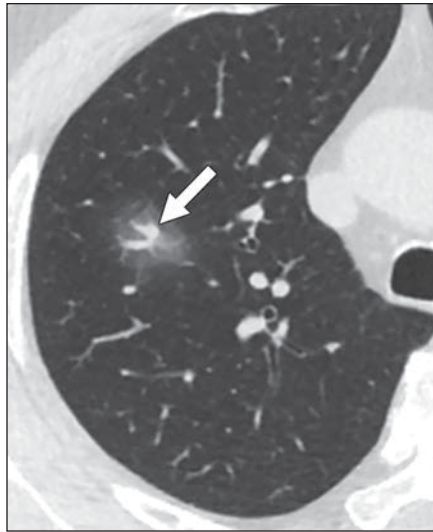Fig. 2—CT features indicating changes in lungs caused by coronavirus disease 2019 pneumonia in eight patients.
A, 52-year-old woman. CT image obtained on day 4 after onset of symptoms shows multiple ground-glass opacities (*box*) in inferior lobe of left lung.
B, 55-year-old man. CT image obtained on day 8 after onset of symptoms shows area of consolidation (*box*) with ground-glass opacities surrounded (*arrow*) in lingual segment of upper lobe of left lung. Air bronchogram can be seen inside consolidation.
C, 32-year-old woman. CT image obtained on day 5 after onset of symptoms shows ground-glass opacities plus reticular pattern (*box*) in peripheral area of inferior lobe of right lung.

(Fig. 2 continues on next page)

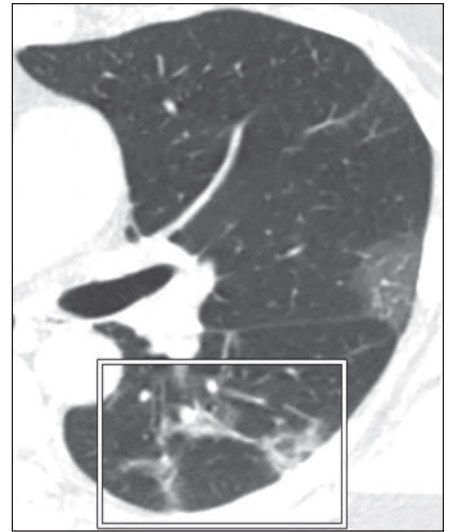
CT Features of COVID-19 Pneumonia



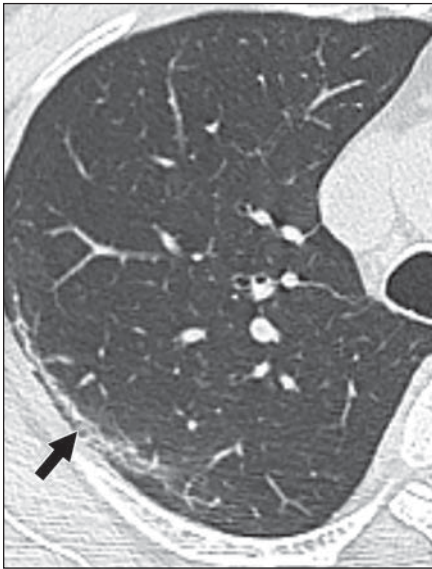
D



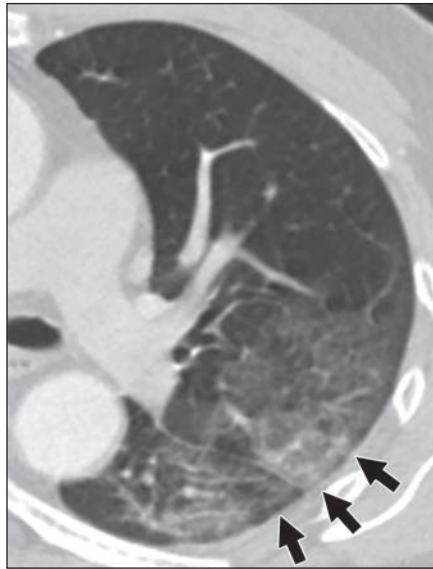
E



F



G



H

Fig. 2 (continued)—CT features indicating changes in lungs caused by coronavirus disease 2019 pneumonia in eight patients.

D, 57-year-old woman. CT image obtained on day 7 after onset of symptoms shows vacuolar sign (*arrow*).

E, 55-year-old man. CT image obtained on day 7 after onset of symptoms shows microvascular dilation sign (*arrow*) in ground-glass opacities.

F, 57-year-old woman. CT image obtained on day 10 after onset of symptoms shows fibrotic streaks (*box*) in inferior lobe of left lung.

G, 39-year-old man. CT image obtained on day 14 after onset of symptoms shows subpleural line (*arrow*) in right lung.

H, 45-year-old man. CT image obtained on day 12 after onset of symptoms shows subpleural transparent line (*arrows*) below left pleura.

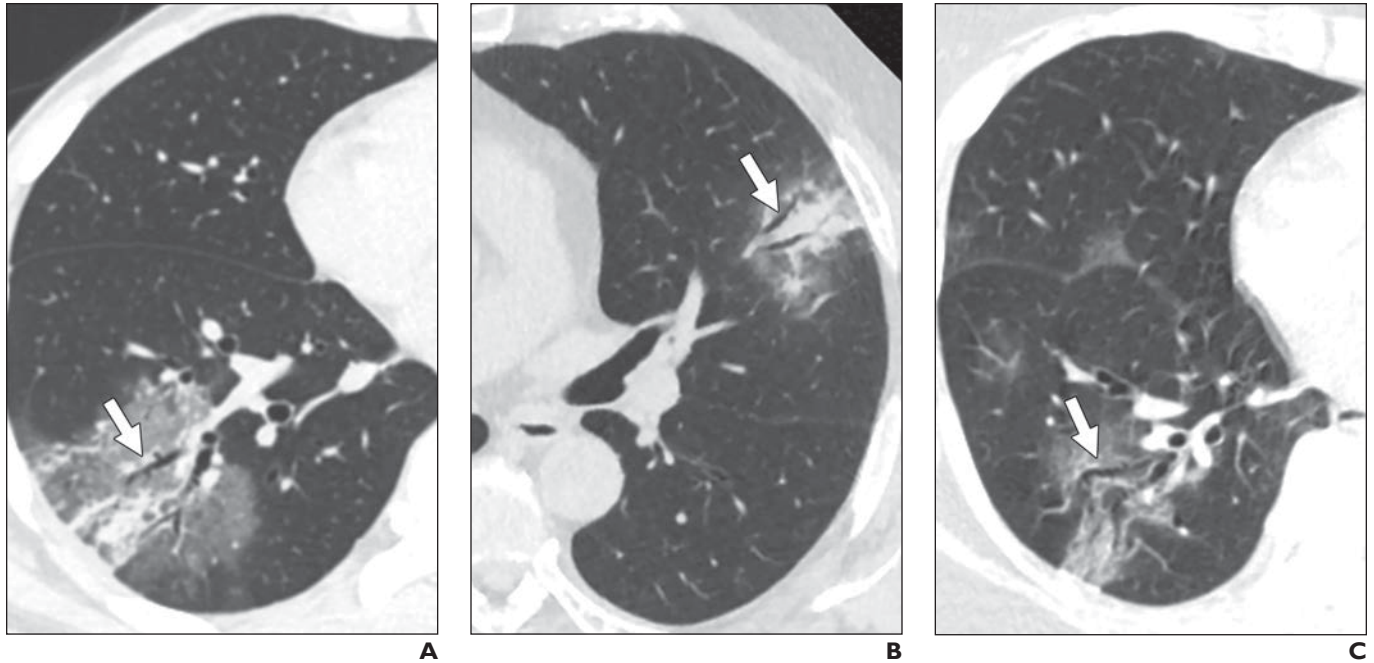


Fig. 3—CT features indicating bronchial changes caused by coronavirus disease 2019 pneumonia.

A, 41-year-old man. CT image obtained on day 7 after onset of symptoms shows air bronchogram (*arrow*) in patchy ground-glass opacities with partial consolidation in inferior lobe of right lung.

B, 55-year-old man. CT image obtained on day 16 after onset of symptoms shows air bronchogram (*arrow*) in consolidation in lingual segment of upper lobe of left lung.

C, 57-year-old woman. CT image obtained on day 16 after onset of symptoms shows bronchus distortion (*arrow*) in ground-glass opacities.

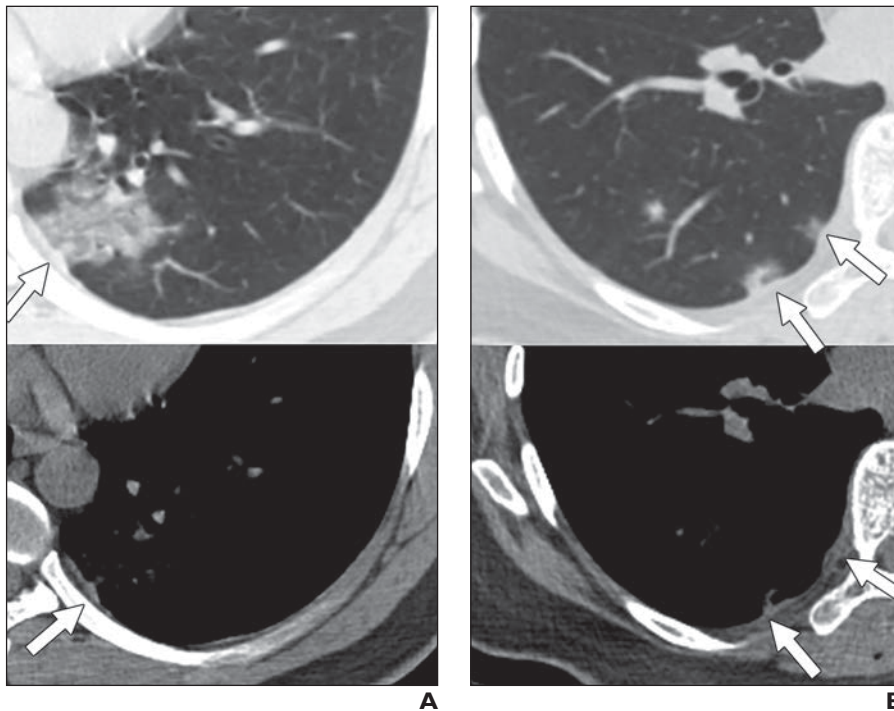


Fig. 4—CT features indicating pleural changes caused by coronavirus disease 2019 pneumonia. Top images were obtained with lung window settings; bottom images were obtained with mediastinal window settings.

A, 36-year-old man. CT images obtained on day 10 after onset of symptoms show mixed ground-glass opacities in inferior lobe of left lung and adjacent pleural thickening (*arrow*).

B, 33-year-old woman. CT images obtained on day 4 after onset of symptoms show patchy area of consolidation with ground-glass opacities surrounded in inferior lobe of right lung and adjacent pleural retraction (*arrows*) and thickening.